UMC Utrecht

Vasculaire pathologie bij pseudoxanthoma elasticum

Wilko Spiering, internist-vasculair geneeskundige

Vasculaire Geneeskunde
UMC Utrecht

Disclosure potential conflicts of interest

Voor bijeenkomst mogelijk relevante relaties:	Bedrijfsnamen
Sponsoring of onderzoeksgeld	• Innovatiefonds Zorgverzekeraars, Vrienden UMC Utrecht, Oogfonds, Stichting PXE Fonds
Honorarium of andere (financiële) vergoeding	• -
Aandeelhouder	• -
Andere relatie, namelijk …	-

Intermittent claudication in 13-year old girl

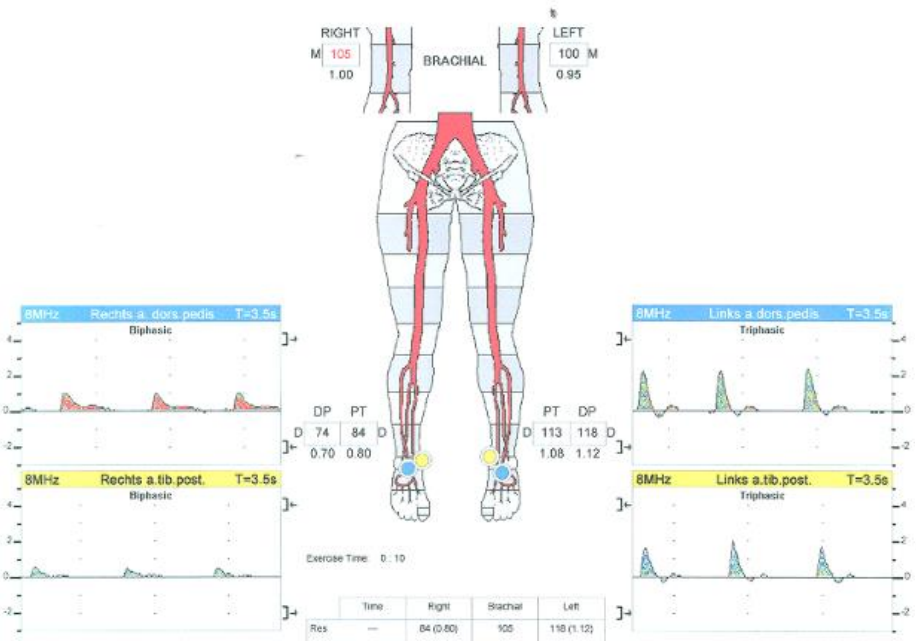

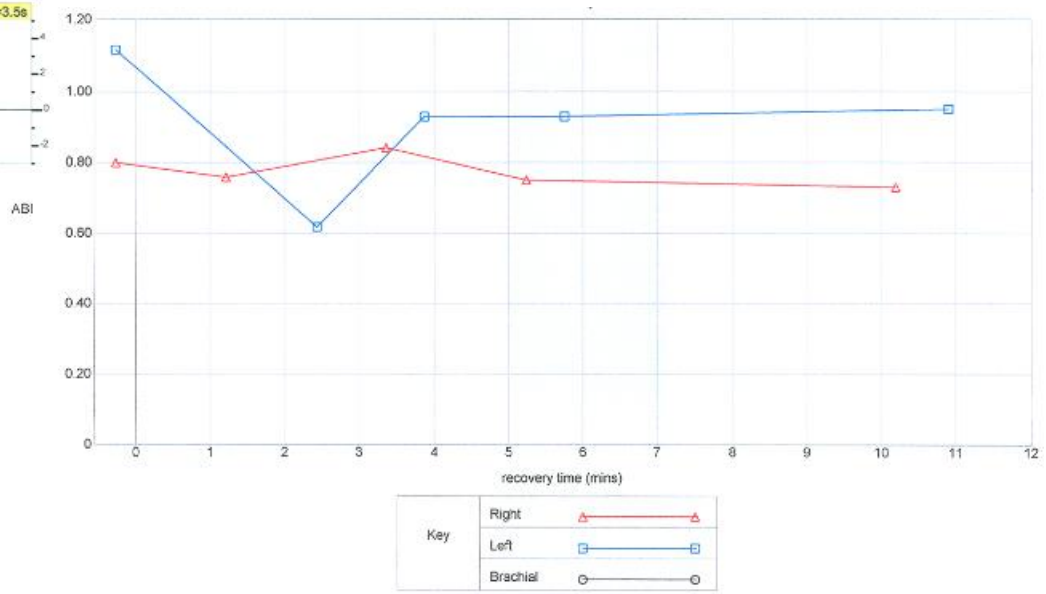

Tromp, Ned Tijdschr Geneeskd 2016

Placental calcifications in 26-year old female

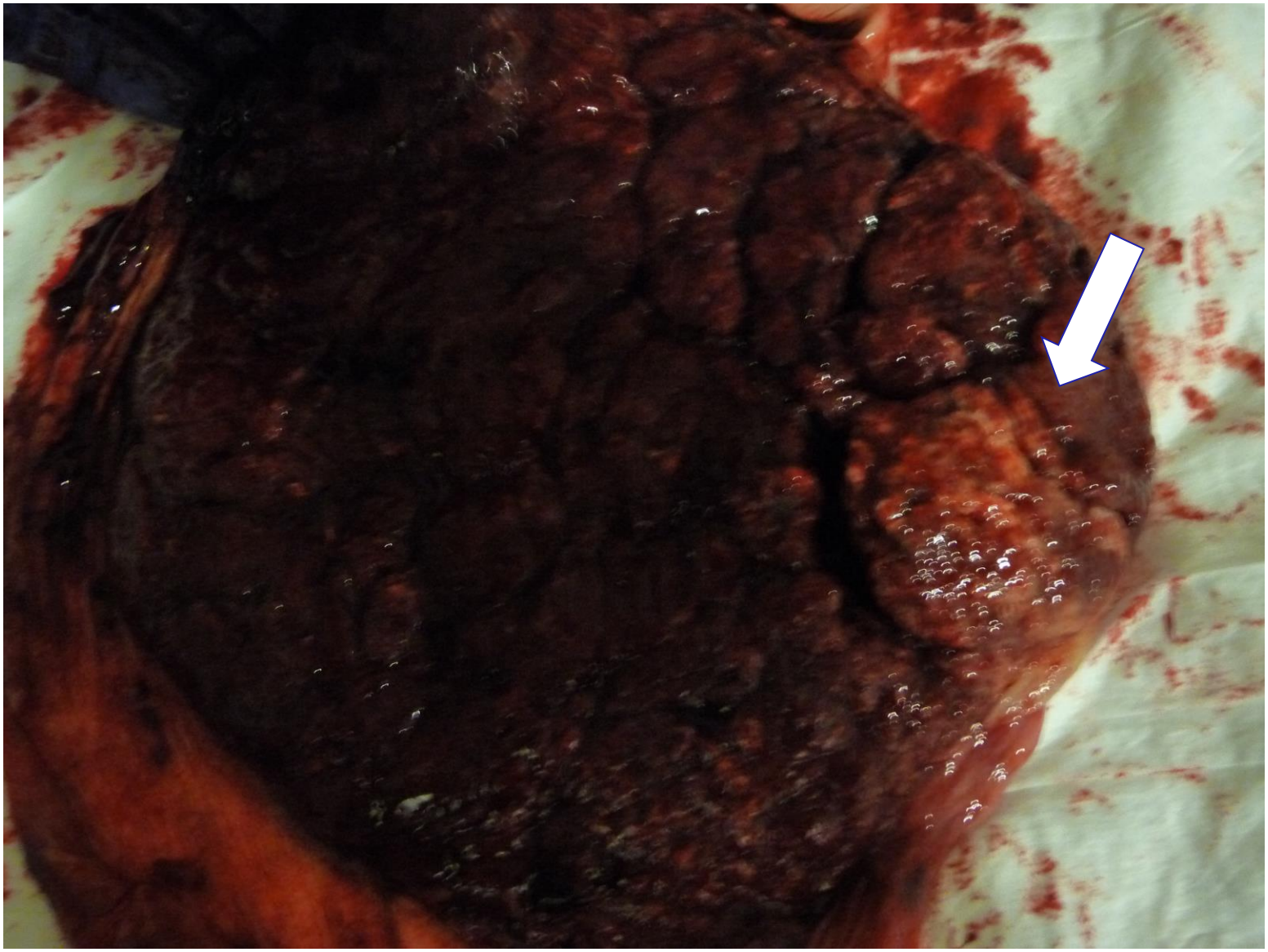

Hydroxyapatite



Atheroslerosis vs. medial calcification

Atherosclerotic calcification

- Eccentric
- Lumen deforming
- Fibrous intimal cap
- Focal elastinolysis
- Vessel stiffening

Medial calcification

- Concentric
- Vessel stiffening
- Medial fibrosis and elastinolysis
- Adventitial inflammation

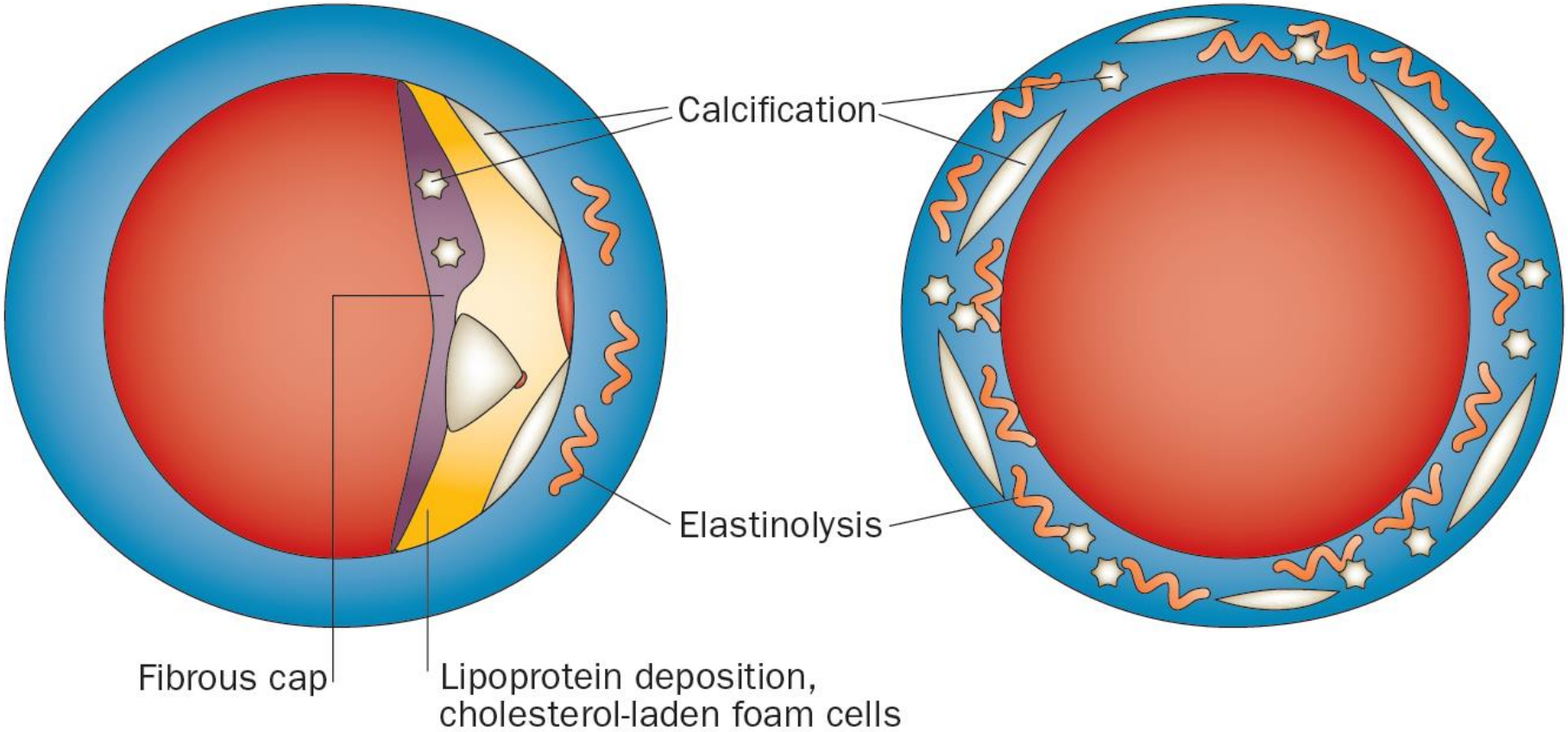

Mönckeberg sclerosis in diabetes mellitus

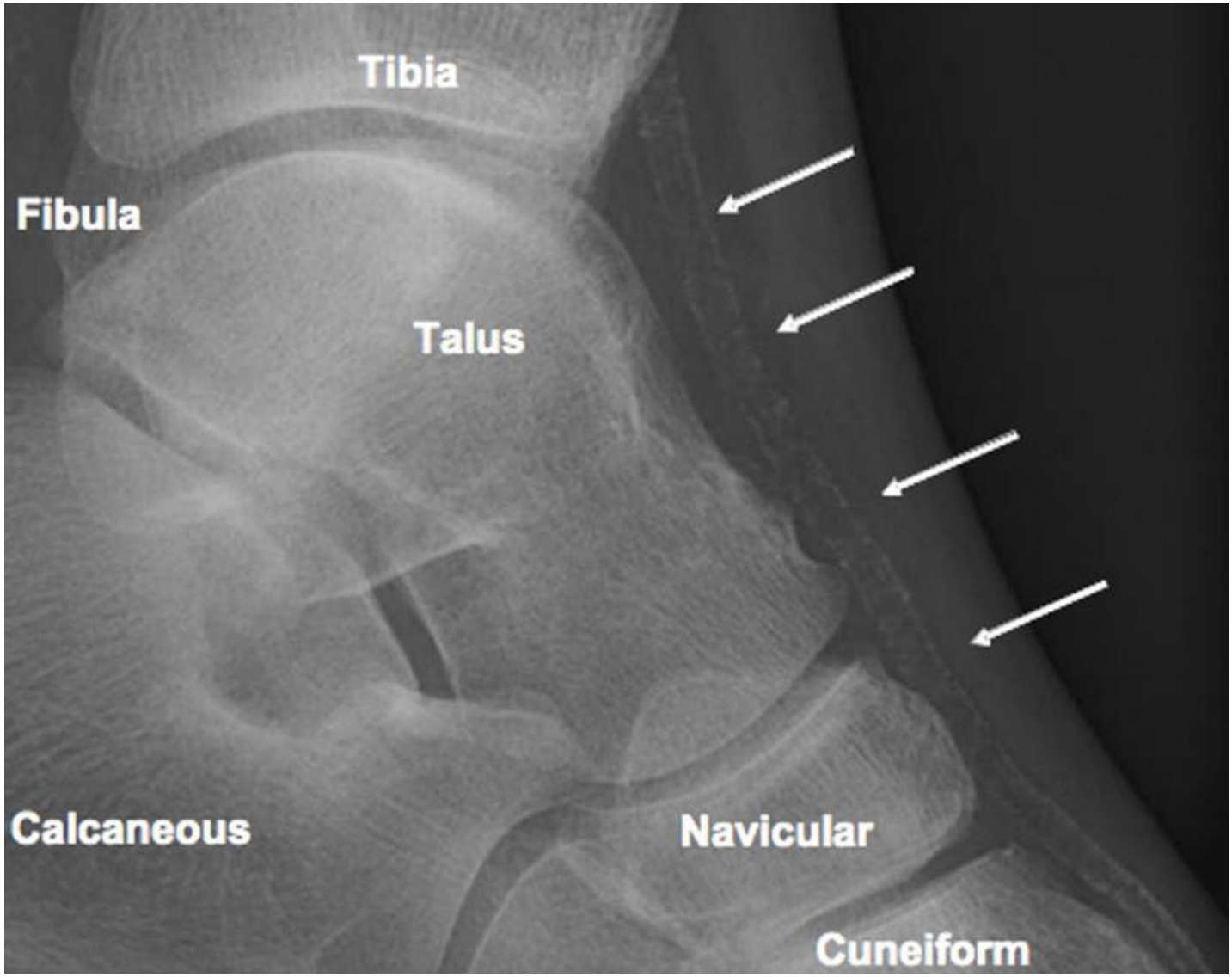

Atheroslerosis vs. medial calcification

	Tissue	CT
Intima		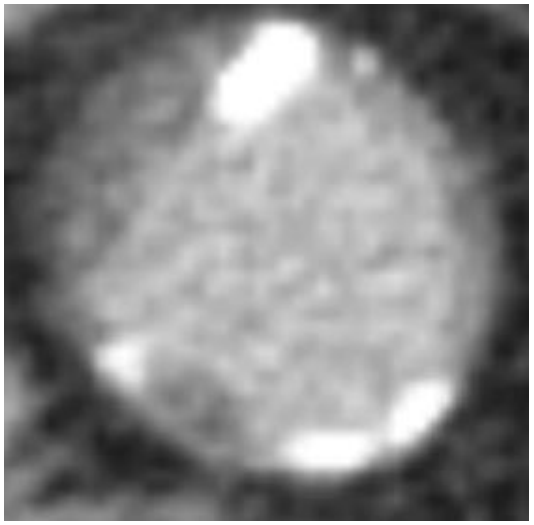
Media	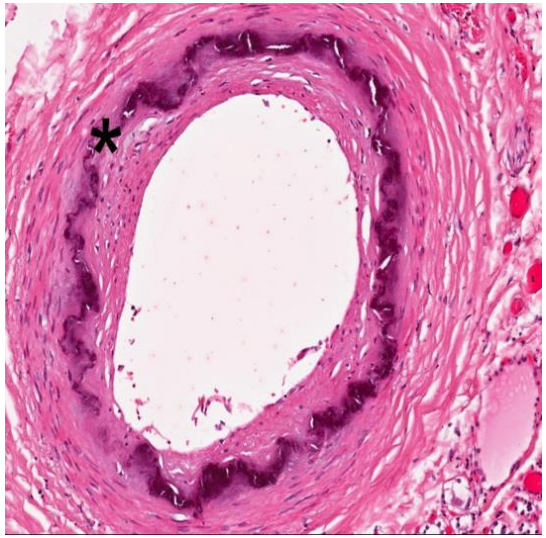	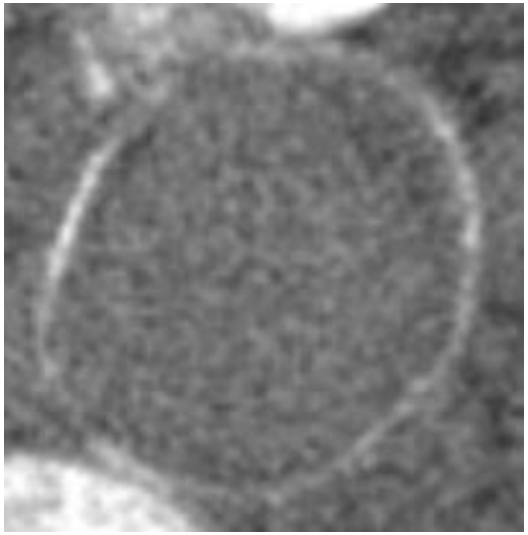

Prevalence of nonatheromatous lesions in PAD

- 176 arterial sections from amputations of 60 patients:
  - 58% diabetes mellitus
  - 35% end-stage renal disease
  - 48% history of smoking
- Most common findings:
  - 72% calcification of the media
  - 68% intimal thickening without lipids
  - 23% atheromas

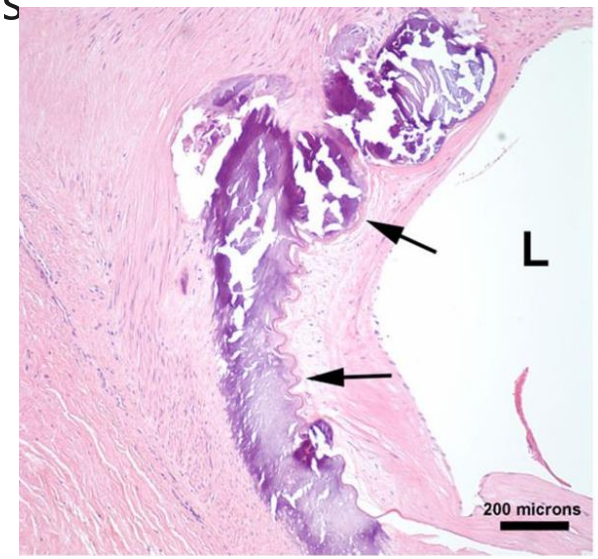

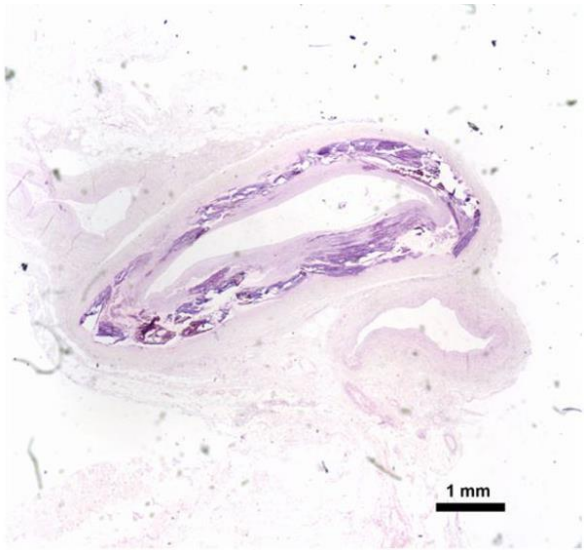

O'Neill, Arterioscler Thromb Vasc Biol 2015

Increased vascular risk with vascular calcification

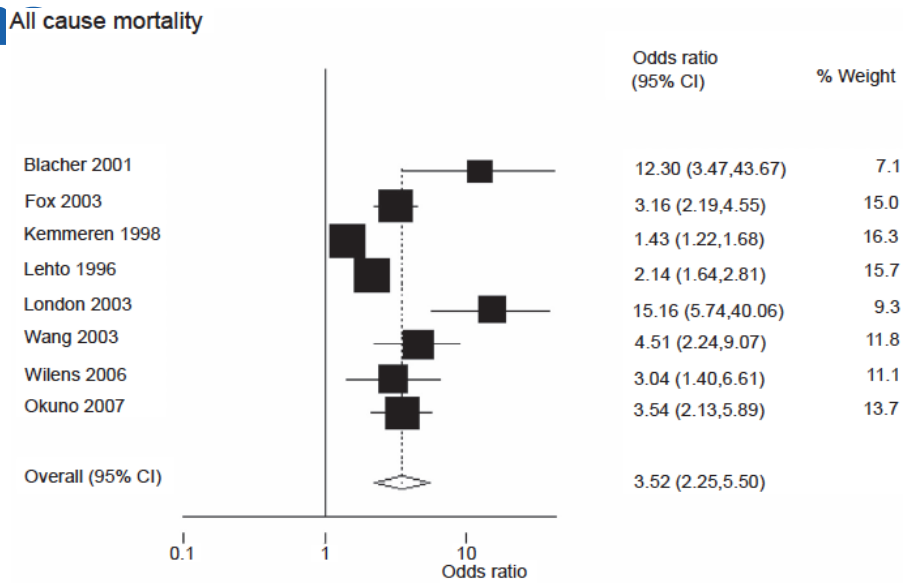

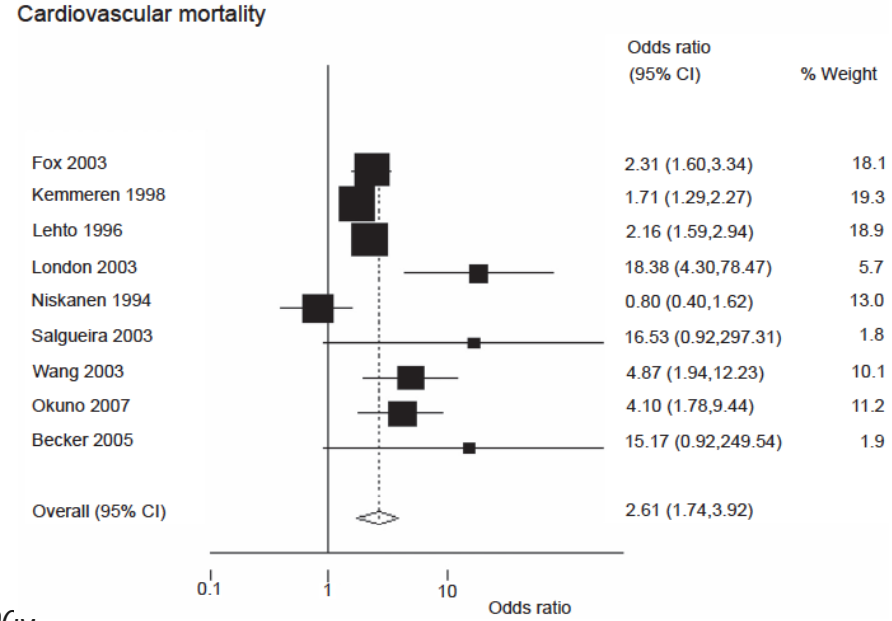

Rennenberg, Vasc Health Risk Manag 2009

Residual cholesterol and inflammatory risk

Residual Inflammatory Risk:
Addressing the Obverse Side of the Atherosclerosis Prevention Coin

Ridker PM. Eur Heart J 2016;37:1720-22

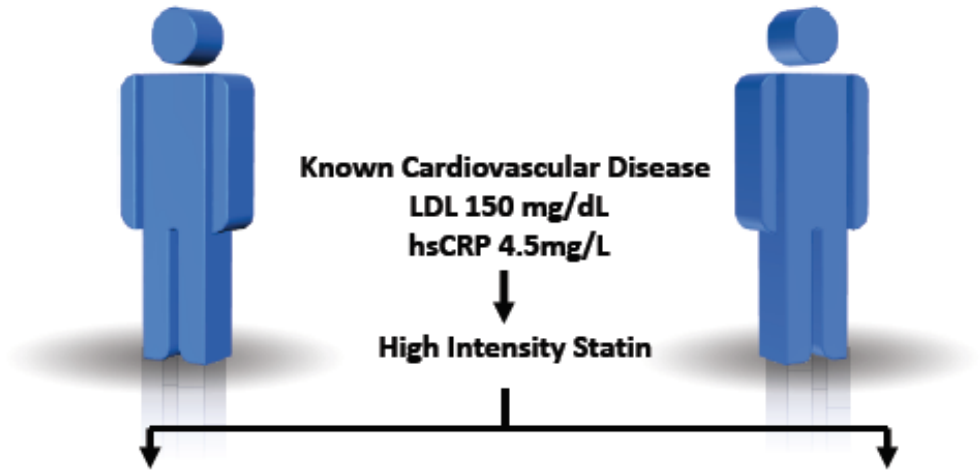

"Residual Cholesterol Risk"

LDL 110 mg/dL
hsCRP 1.8 mg/L

↓

Additional
LDL Reduction

IMPROVE-IT : Ezetimibe 6% RRR
FOURIER/SPIRE: PCSK9 Inhibition q2 weeks 15% RRR

"Residual Inflammatory Risk"

LDL 80 mg/dL
hsCRP 3.8 mg/L

↓

Additional
Inflammation Reduction

No Prior Proof of Concept
Canakinumab 150mg SC q 3 months 15%RRR

Residual calcification risk?

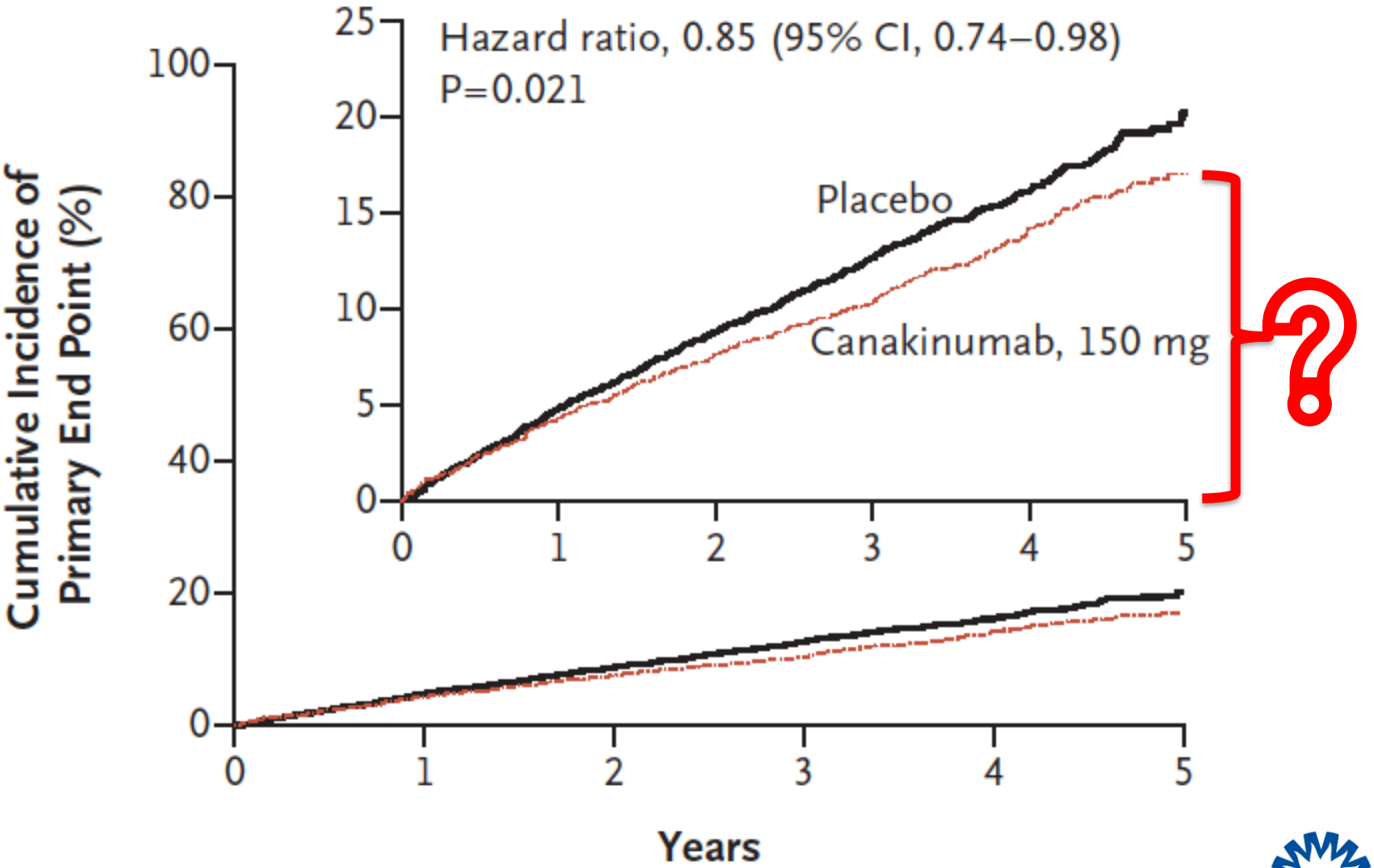

Ridker, N Engl J Med 2017

Inherited arterial calcification disorders

Disease	OMIM	Gene(s)	Phenotype
Generalized arterial calcification of infancy (GACI)	#208000	*ENPP1, ABCC6*	Arterial calcification, joint and spine ossification
Pseudoxanthoma elasticum (PXE)	#264800	*ABCC6*	Calcification skin, eyes, and cardiovascular system
Calcification of joints and arteries (CALJA)	#211800	*NT5E*	Vascular and joint calcification
Idiopathic basal ganglion calcification (IBGC1)	#213600	*SLC20A2, XPR1, PDGFRB, PDGFB*	Vascular and pericapillary calcifications brain
Hutchinson-Gilford progeria syndrome (HGPS)	#176670	*LMNA*	Calcification aorta and aortic valves, premature aging
Hyperphosphatemic familial tumoral calcinosis (HFTC)	#211900	*KL, GALNT3, FGF23*	Calcification skin, placental and femoral arteries, periarticular tissue

Inherited arterial calcification disorders

Disease	OMIM	Gene(s)	Phenotype
Singleton-Merten syndrome	#182250	*IFIH1, DDX58*	Arterial and aortic valve calcification, premature loss secondary teeth, glaucoma, skeletal abnormalities
Keutel syndrome	#245150	*MGP*	Arterial and cartilage calcification
Gaucher disease, type IIIC	#231005	*GBA*	Cardiovascular calcifications

Hutchinson-Gilford progeria syndrome

Pseudoxanthoma elasticum

- Prevalence 1/50,000-100,000
- Autosomal recessive
- Male:female = 1:2
- *ABCC6*
- Clinical presentation:
  - Cutaneous (pseudoxanthomas neck, armpit, elbow pit, groin)
  - Ophtalmic (angioid streaks, peau d'orange, neovascularisations)
  - Vascular (medial calcification)

History

- 1881 cutaneous manifestations (Rigal)
- 1889 French soldier with xanthomatosis and hematemesis (Chauffard)
- 1896 skin biopsy with elastin fractures: *pseudo*xanthoma elasticum (Darier)
- 1929 association with retinal angioid streaks (Grönblad and Strandberg)
- 1963 first description 12 patients: skin, eye and vascular abnormalities (Goodman)



Cutaneous manifestation

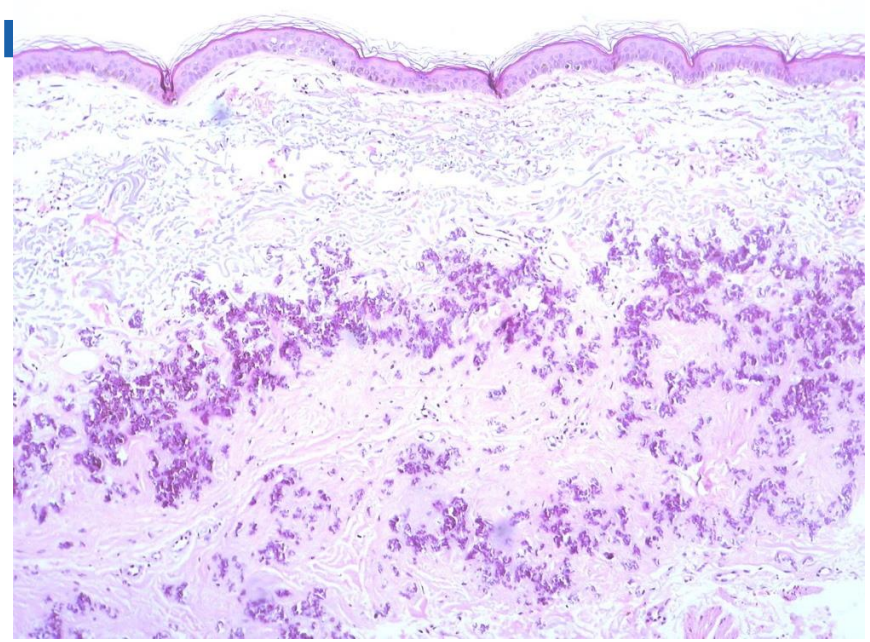

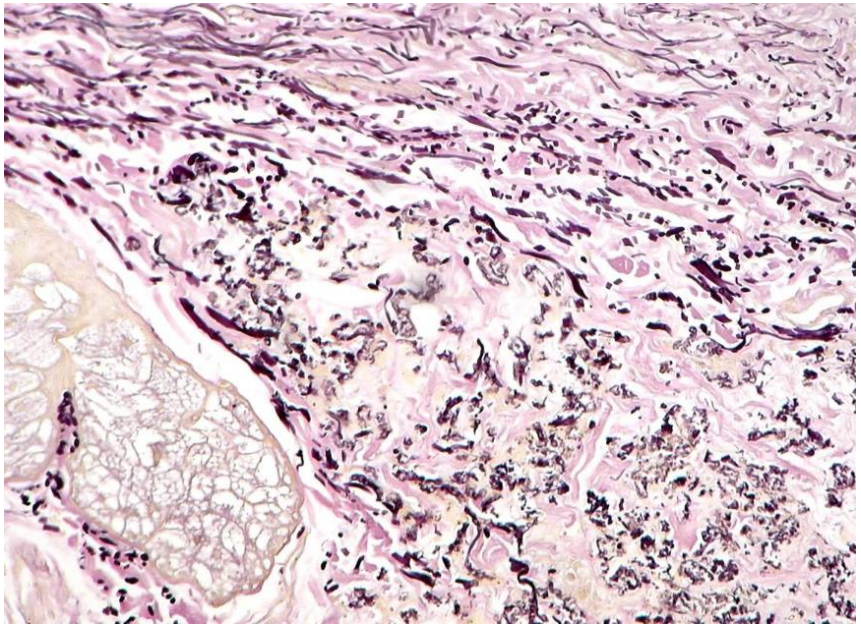

Skin calcification in 42-year old female

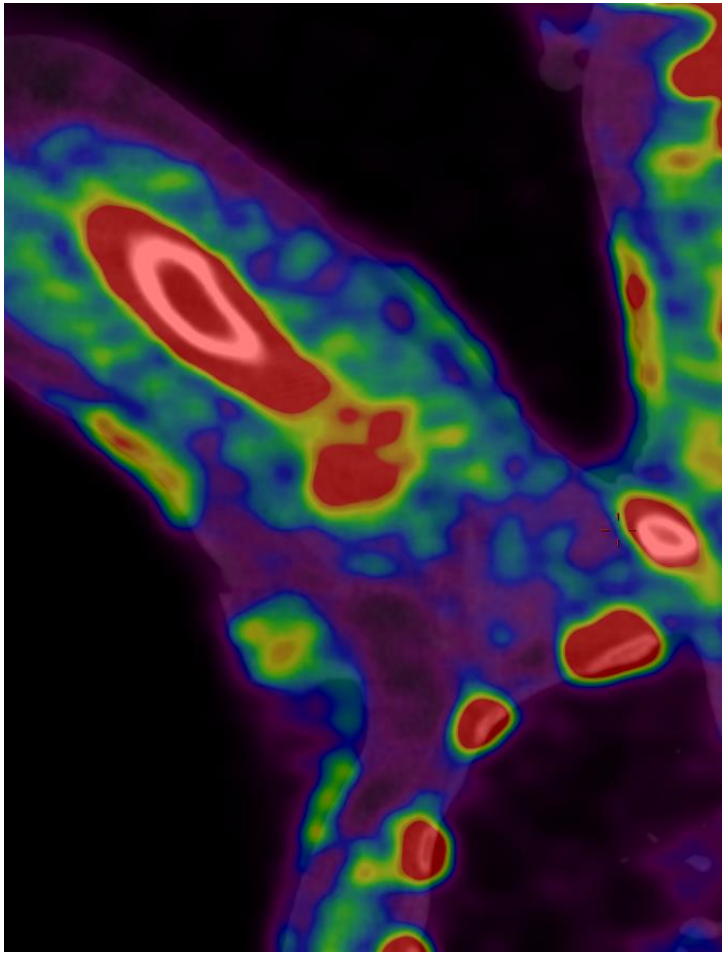

Oudkerk, JACC Cardiovasc Imaging 2016

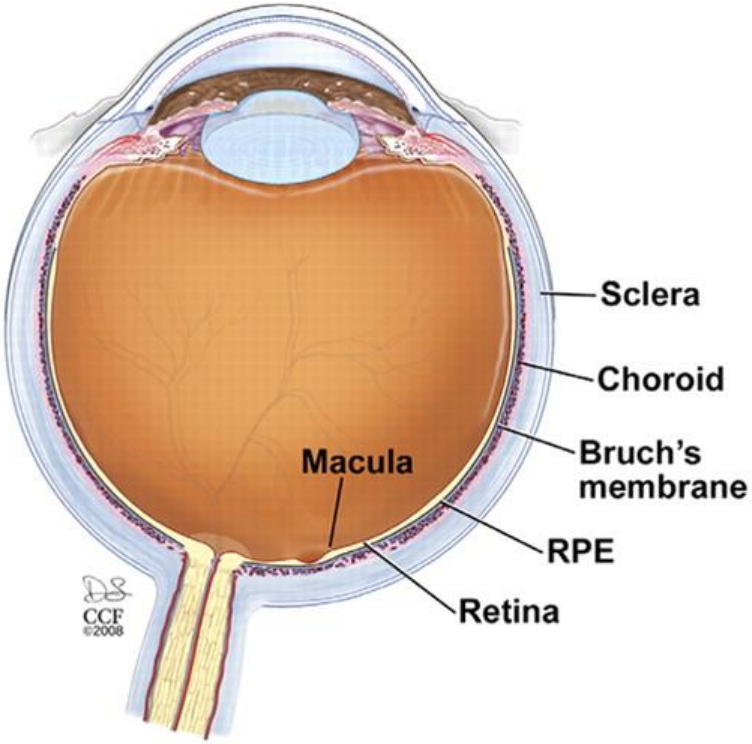
Sclera
Choroid
Bruch's membrane
Macula
RPE
Retina
CCF
©2008

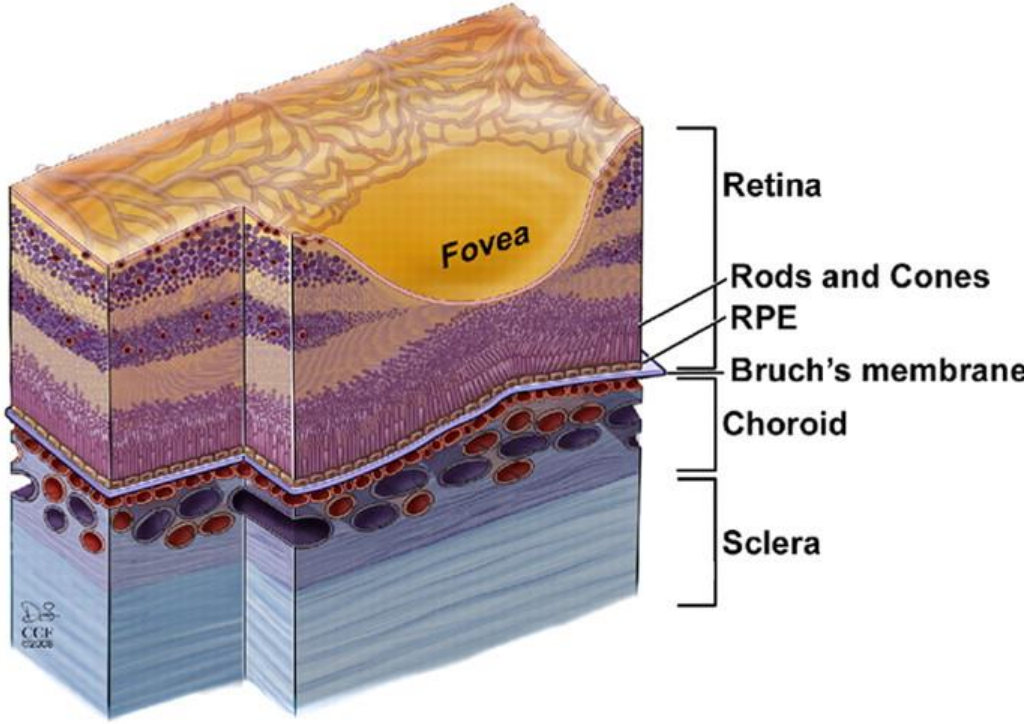
Fovea
Retina
Rods and Cones
RPE
Bruch's membrane
Choroid
Sclera

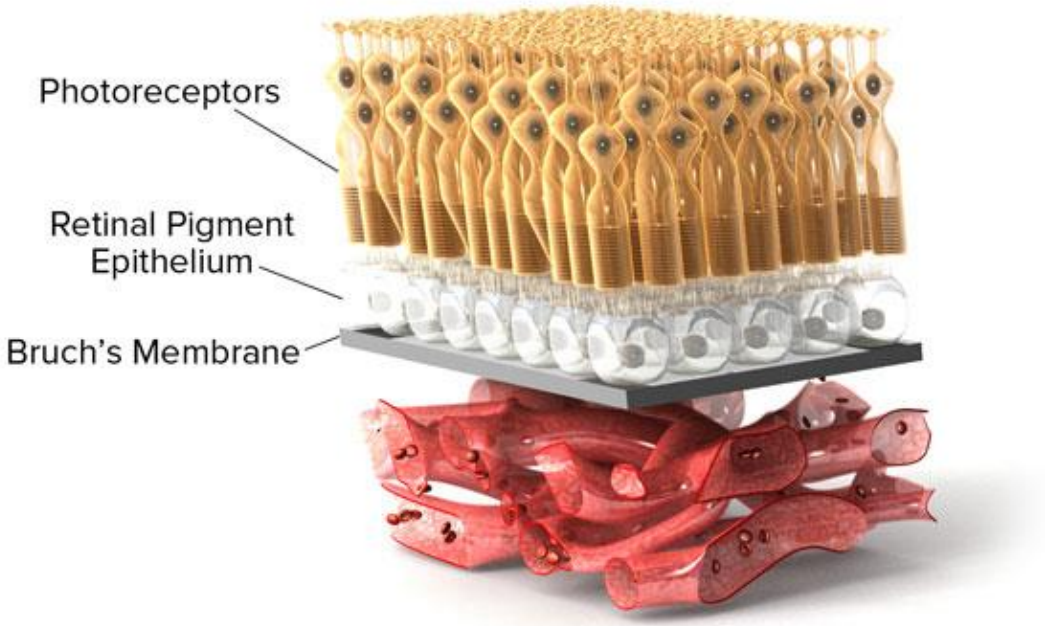
Photoreceptors
Retinal Pigment Epithelium
Bruch's Membrane

Vascular wall

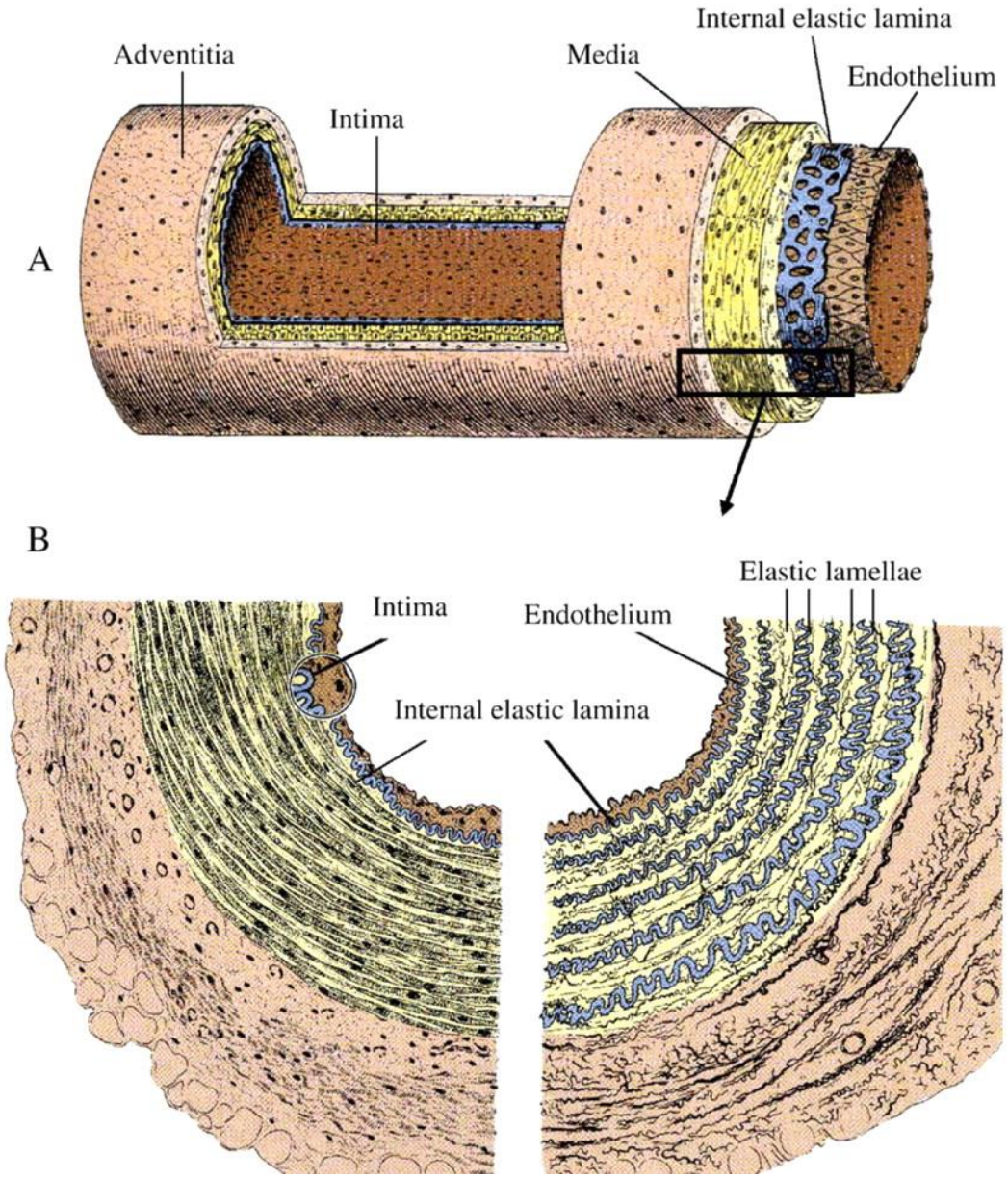

Vascular calcification in 56-year old female

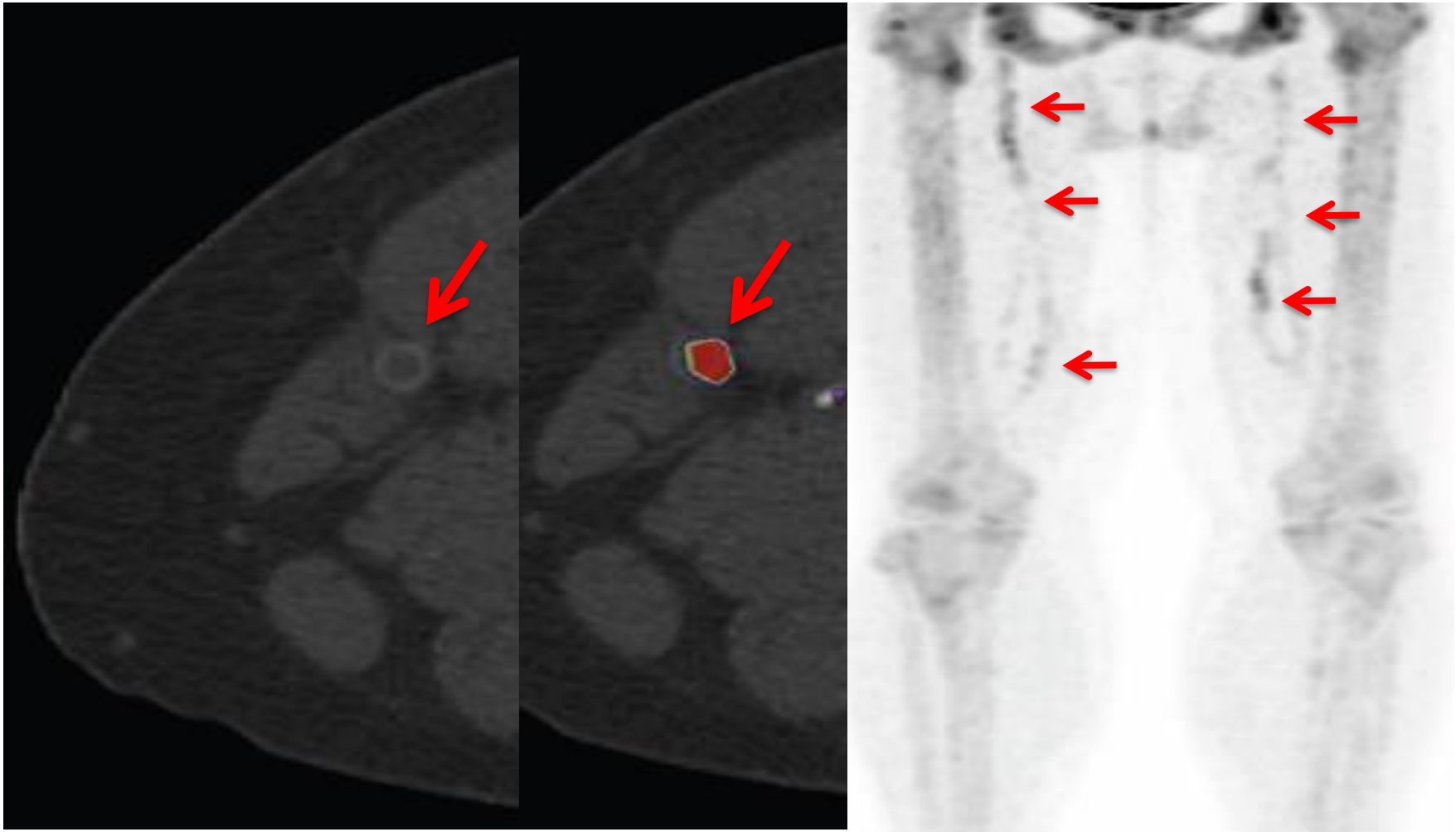

Oudkerk, JACC Cardiovasc Imaging 2016

Vascular calcification in 69-year old male

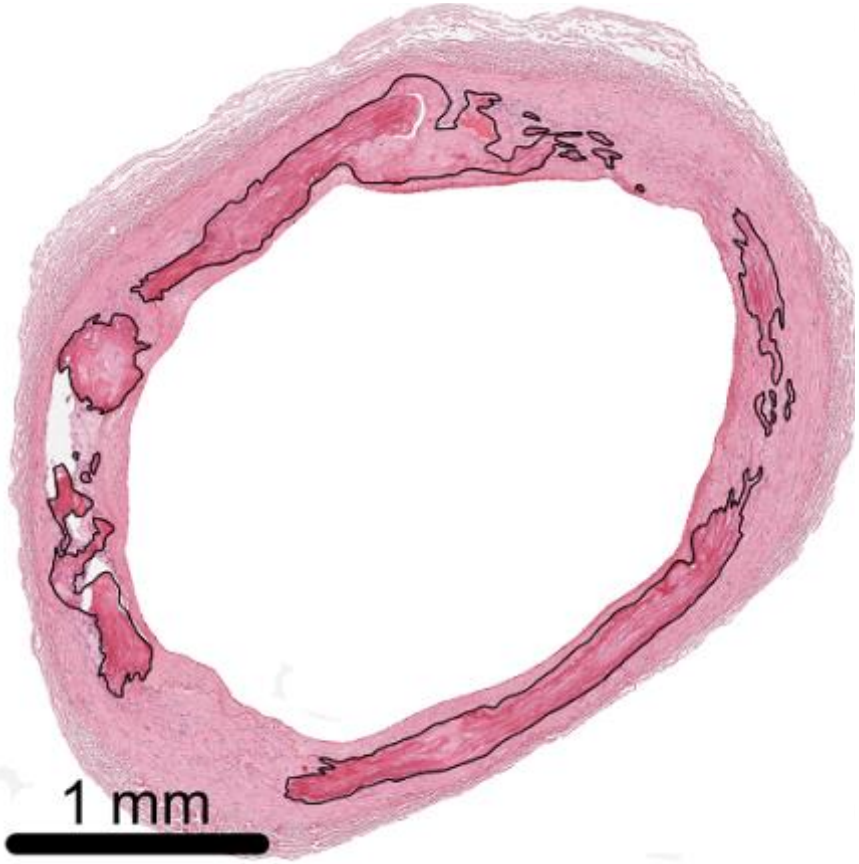

Vos, submitted

Pyrophosphate in *ABCC6 -/-* mice

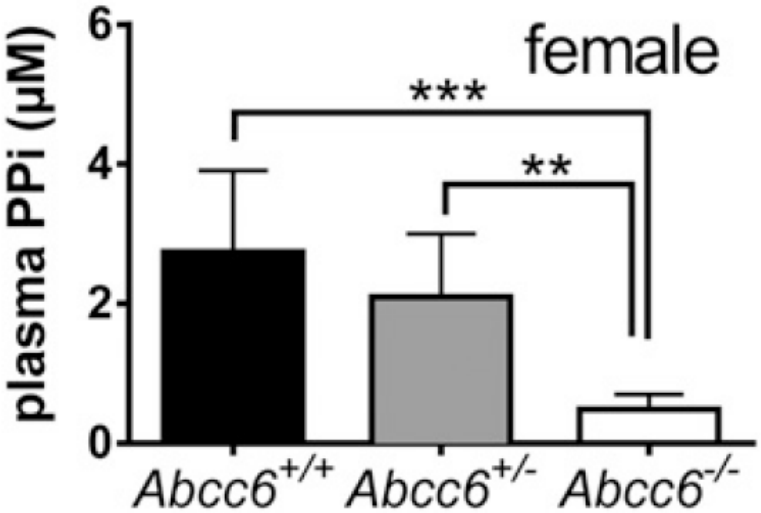

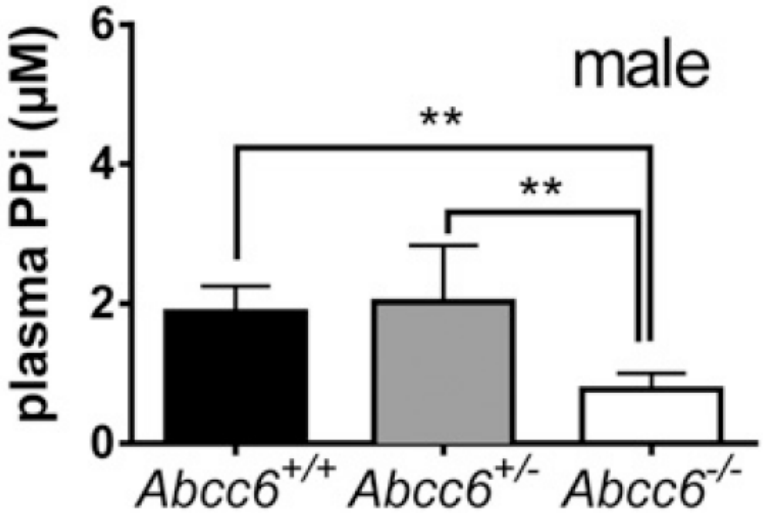

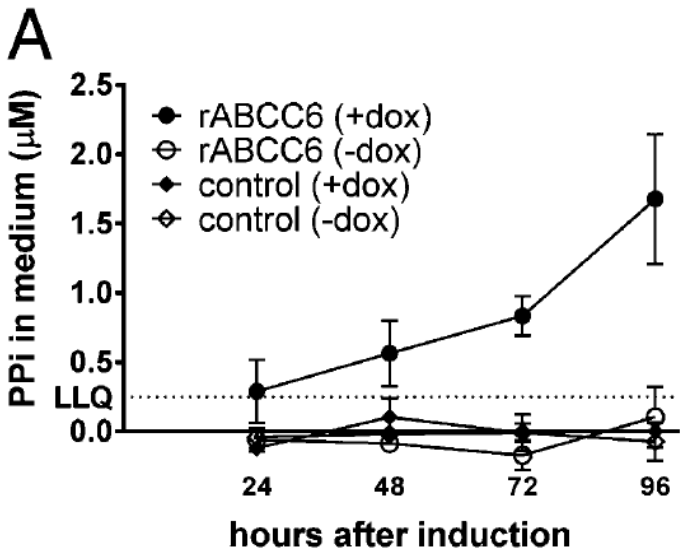

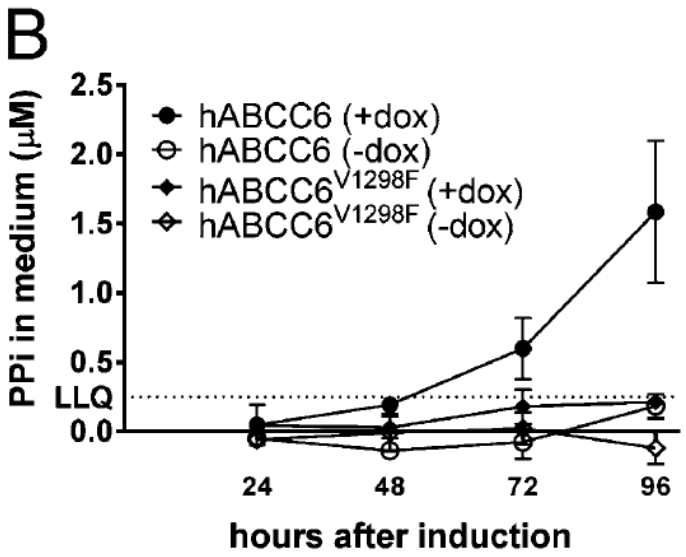

Jansen, PNAS 2013

Pyrophosphate in PXE patients

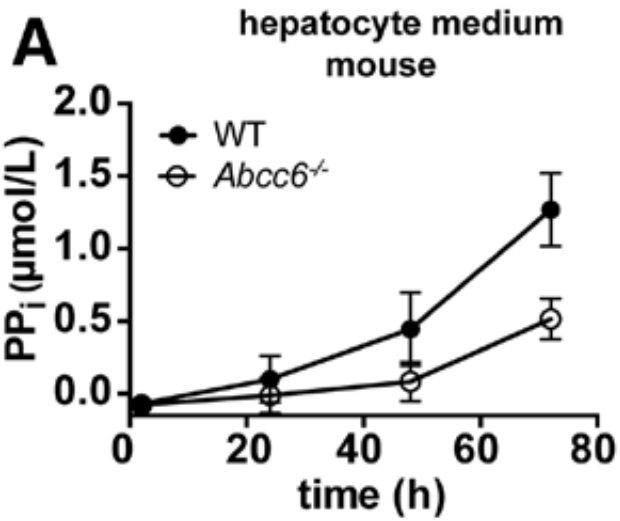

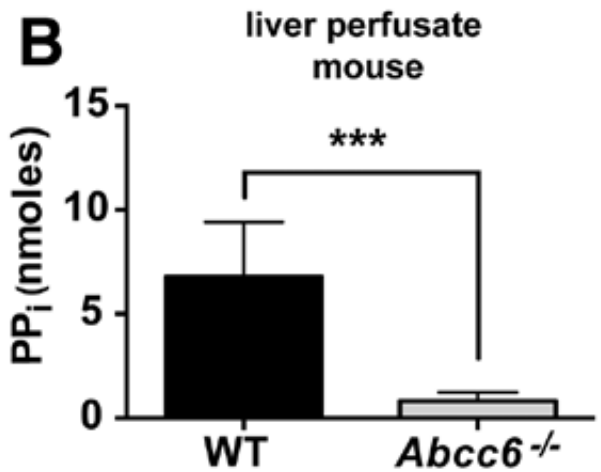

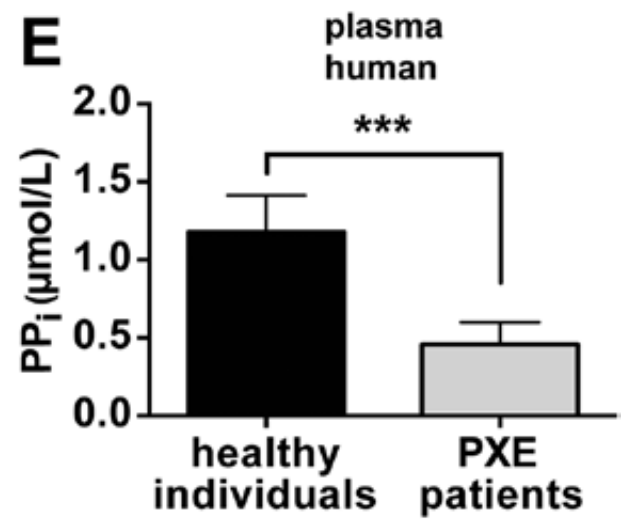

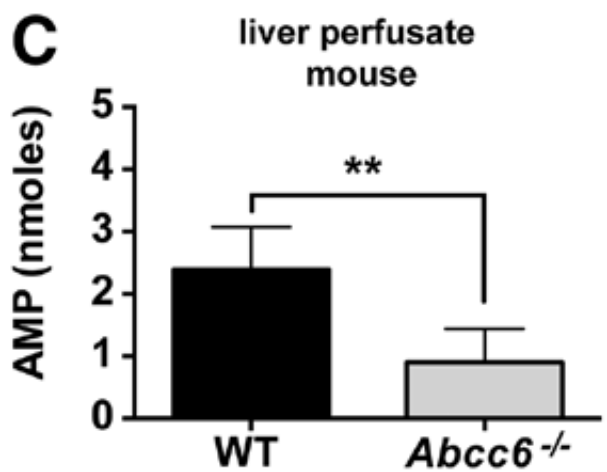

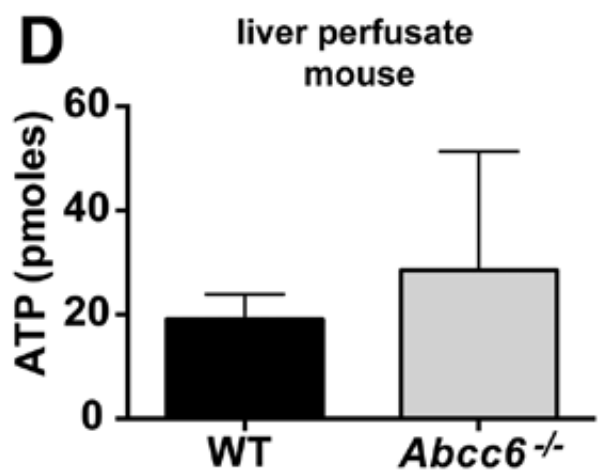

Jansen, Arterioscler Thromb Vasc Biol 2014

Calcification mechanisms

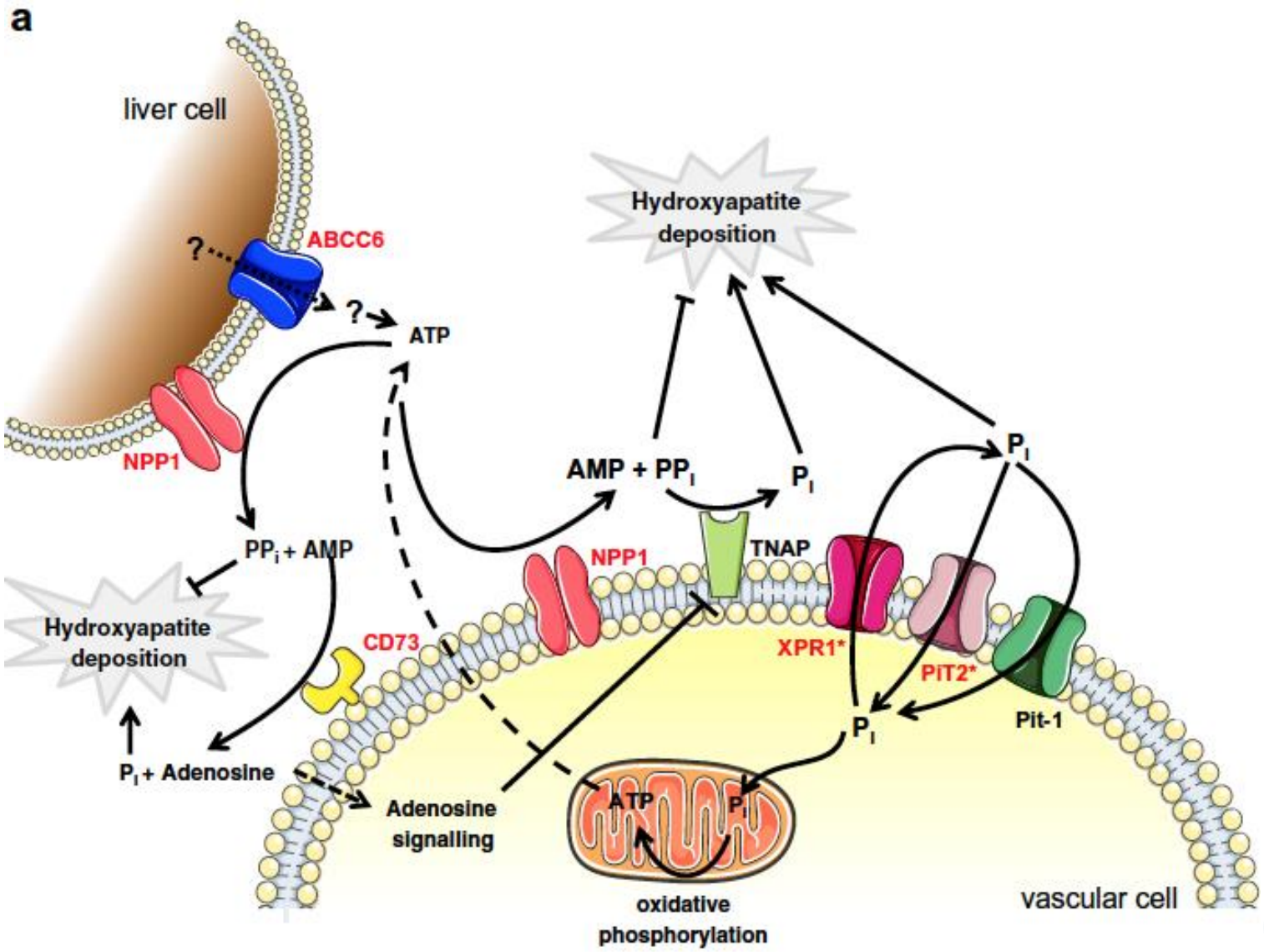

Nitschke, Curr Osteoporos Rep 2017

Landelijk Expertisecentrum PXE (LEP)

- Gestart in 2013
- Multidisciplinair team:
  - Internist-vasculair geneeskundige
  - Oogarts
  - Klinisch geneticus
  - Radioloog
  - Dermatoloog
  - Vaatchirurg
- 203 patiënten (240 gescreend)
- Onderzoeksdatabase

Werkwijze LEP

- Vaststellen klinische diagnose PXE
- Genetische screening
- Huid: foto's
- Ogen: foto's, beoordeling PXE-oogarts
- Bloedvaten:
  - Inventarisatie risicofactoren hart- en vaatziekten
  - Looptest
  - Vaatstijfheid (pulse wave velocity)
  - Intima-media-dikte
  - CT total body
- Intra-oculaire ooginjecties VEGF-remmers indien nodig
- Behandeling cardiovasculaire risicofactoren
- Jaarlijkse controle

Pulse wave velocity

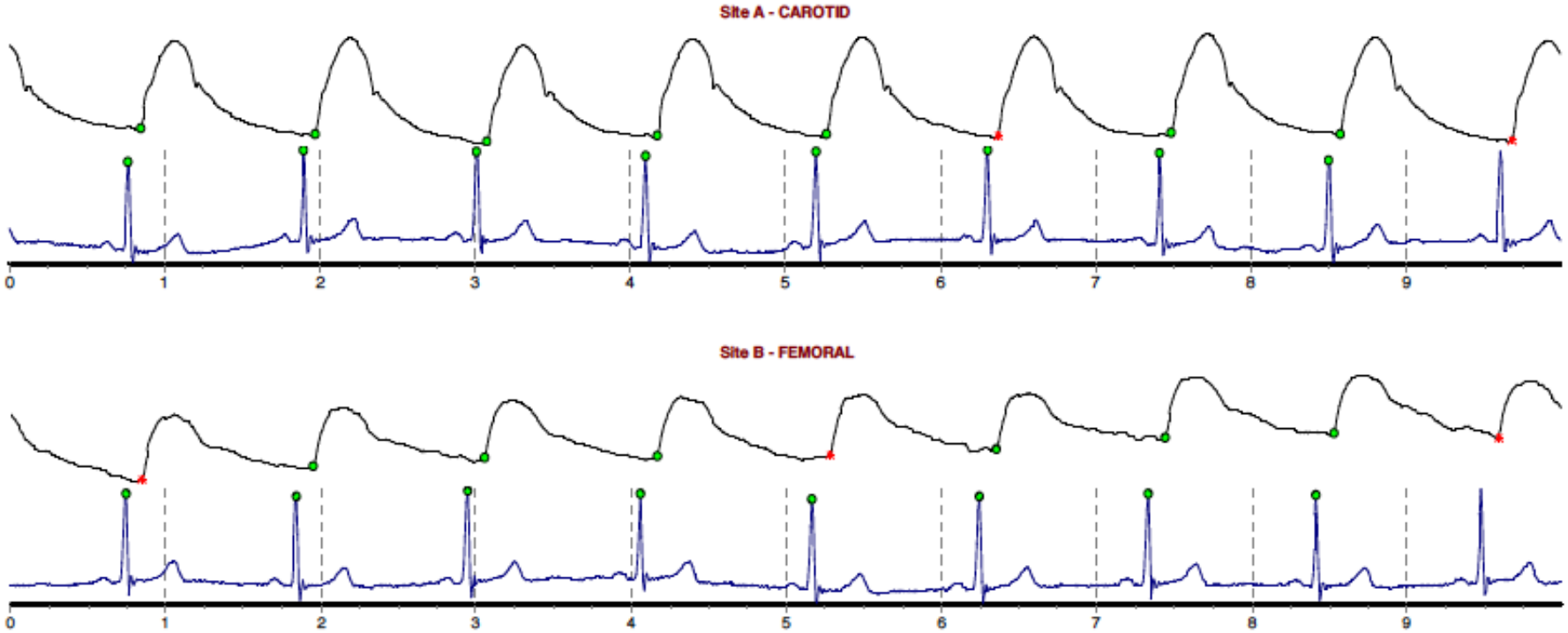

PULSE WAVE VELOCITY CALCULATION

Site A-B	MeanT(ms)	SD(ms)	N	HR(bpm)
ECG-CAR	72,2	2,7	7	54
ECG-FEM	109,1	2,1	6	55
CAR-FEM	36,9	3,4		

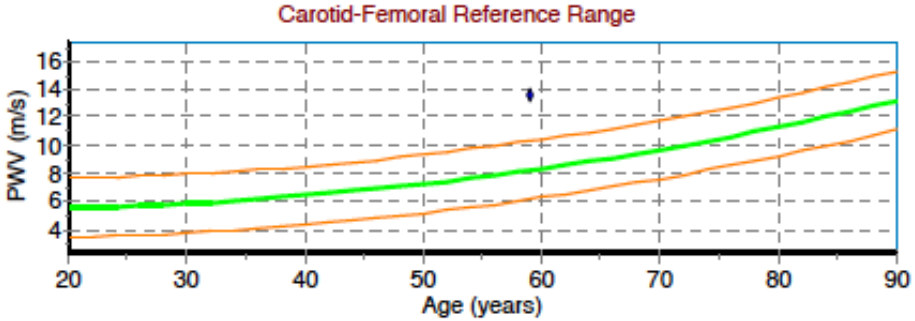

AtCor Medical SCOR-CvMS 8.2 (01473) 130 DATA MM3 - [PVH] 16 jul 2014

Pulse Wave Velocity = 13,5 ± 1,3 (m/s)

(9%SD)

Prevalence of PXE in the Netherlands

Province	Inhabitants	PXE patients	Density
Groningen	582,649	8	72,831
Friesland	646,092	5	129,218
Drenthe	488,871	6	81,479
Overijssel	1,142,360	8	142,795
Flevoland	403,280	4	100,820
Gelderland	2,031,123	26	78,120
Utrecht	1,268,489	31	40,919
Noord-Holland	2,775,617	51	54,424
Zuid-Holland	3,607,150	39	92,491
Zeeland	381,182	4	95,296
Noord-Brabant	2,495,107	17	146,771
Limburg	1,115,805	4	278,951
TOTAL	**16,937,725**	**203**	**83,437**

Patient characteristics PXE vs. control

	PXE (n=104)	Control (n=93)	P-value
Sex (male)	39 (38%)	42 (45%)	0.275
Age, years	54 ± 13	54 ± 16	0.884
SBP, mmHg	137 ± 23	130 ± 21	0.062
DBP, mmHg	80 ± 12	76 ± 12	0.009
BMI, kg/m^2	25.9 ± 4.6	26.0 ± 6.4	0.865
Current smoking, n (%)	16 (16%)	19 (20%)	0.220
Diabetes mellitus, n (%)	4 (4%)	7 (8%)	0.261
eGFR <30 mL/min/1.73m^2, n (%)	0 (0%)	6 (7%)	0.009
Reason for full body CT			
PXE	103 (100%)	0 (0%)	-
Fever of unknown origin	0 (0%)	63 (68%)	-
Follow-up for melanoma	0 (0%)	24 (26%)	-
Suspected malignity	0 (0%)	6 (6%)	-

Kranenburg, Atherosclerosis 2017

Vascular calcifications in PXE

	PXE (n=104)	Control (n=93)	P-value
Intracranial internal carotid arteries	78 (75%)	41 (44%)	**<0.001**
Extracranial carotid arteries	47 (45%)	40 (43%)	0.776
Vertebral arteries	19 (17%)	9 (10%)	0.148
Coronary arteries	54 (52%)	43 (46%)	0.476
Aortic valve*	17 (16%)	16 (17%)	1.000
Mitral valve	1 (1%)	1 (1%)	0.102
Arm arteries	21 (20%)	3 (3%)	**<0.001**
Thoracic aorta	50 (48%)	52 (56%)	0.318
Abdominal aorta	74 (71%)	59 (63%)	0.287
Mesenteric arteries	28 (27%)	24 (26%)	0.873
Internal iliac arteries	58 (56%)	48 (52%)	0.570
External iliac arteries	17 (16%)	28 (30%)	**0.027**
Femoral-poplitial arteries	77 (74%)	41 (44%)	**<0.001**
Subpoplitial arteries	87 (84%)	35 (38%)	**<0.001**

Kranenburg, Atherosclerosis 2017

Arterial calcification phenotype in PXE

Kranenburg, Atherosclerosis 2017

Patient characteristics

	Cerebral disease (n=31)	No cerebral disease (n=147)	P-value
Sex (male)	8 (26%)	53 (36%)	0.275
Age, years	61 ± 12	52 ± 15	**0.003**
SBP, mmHg	137 ± 22	126 ± 21	**0.007**
DBP, mmHg	73 ± 9	74 ± 11	0.876
Smoking, pack years (IQR)	3 (0-20)	5 (0-13)	0.283
CAD, n (%)	3 (10)	7 (5)	0.280
PAD, n (%)	17 (55)	56 (38)	0.085
Family history CVD, n (%)	12 (39)	35 (24)	0.096
Blood pressure-lowering medication, n (%)	13 (42)	29 (20)	**0.008**
Lipid-lowering medication, n (%)	19 (61)	45 (31)	**0.001**
Glucose, mmol/L	6.2 (2.1)	5.5 (1.2)	0.089
LDL-c, mmol/L	2.9 (1.0)	3.0 (1.0)	0.589
eGFR, ml/min/1.73m2	85 (76-90)	90 (82-90)	**0.012**

Kauw, J Neurol Sci 2017

Cerebral disease in PXE

	n	%
Ischemic stroke	15	8
TIA	13	7
Parkinson's disease	2	1
Intracranial hemorrhage	1	1
Cerebral aneurysm	1	1
Vascular dementia	1	1
Sinus thrombosis	1	1
Bilateral carotid agenesis	1	1
Migraine	1	1

Kauw, J Neurol Sci 2017

Intima-media thickness in PXE vs. expected

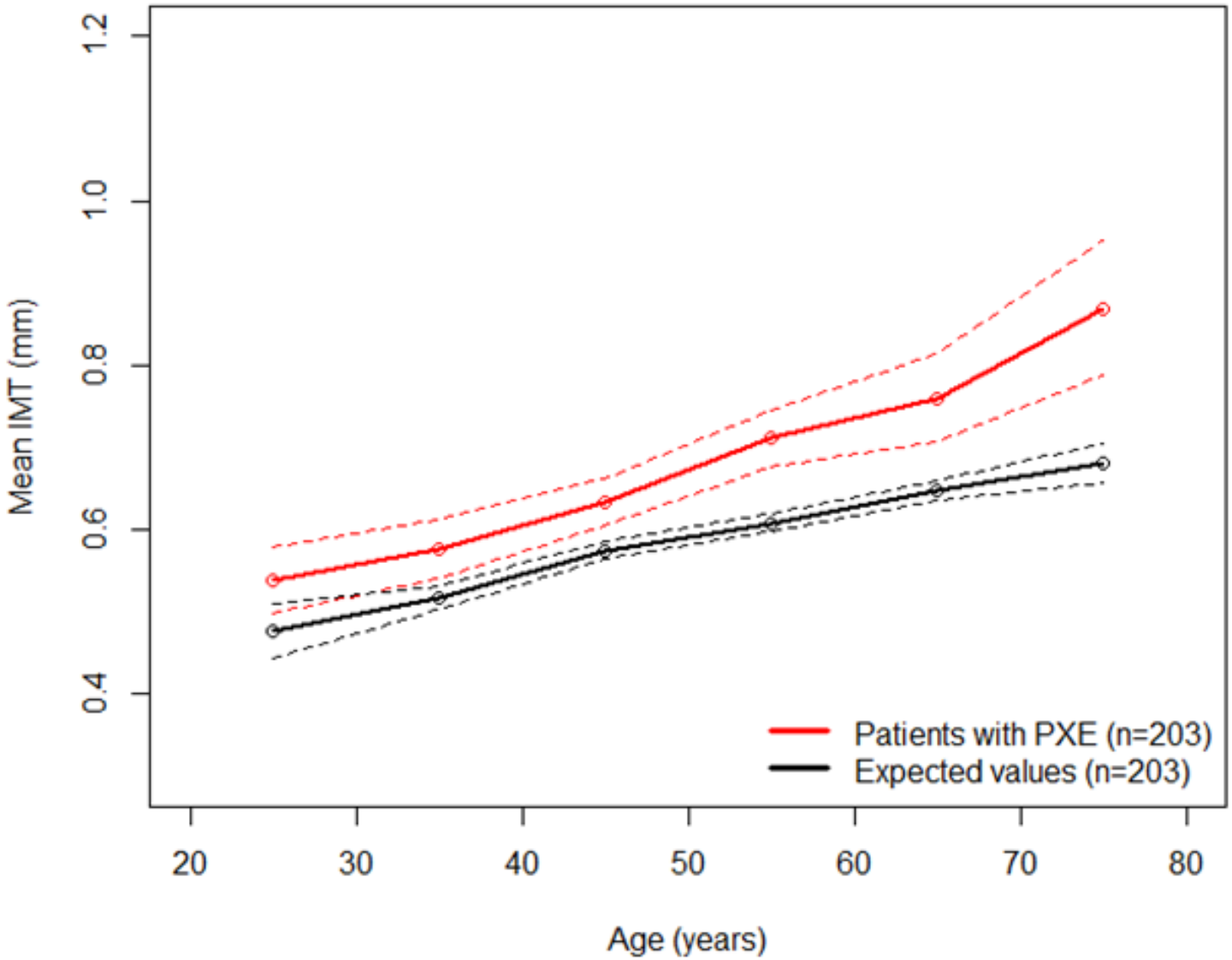

Kranenburg, submitted

Pulse wave velocity in PXE vs. expected

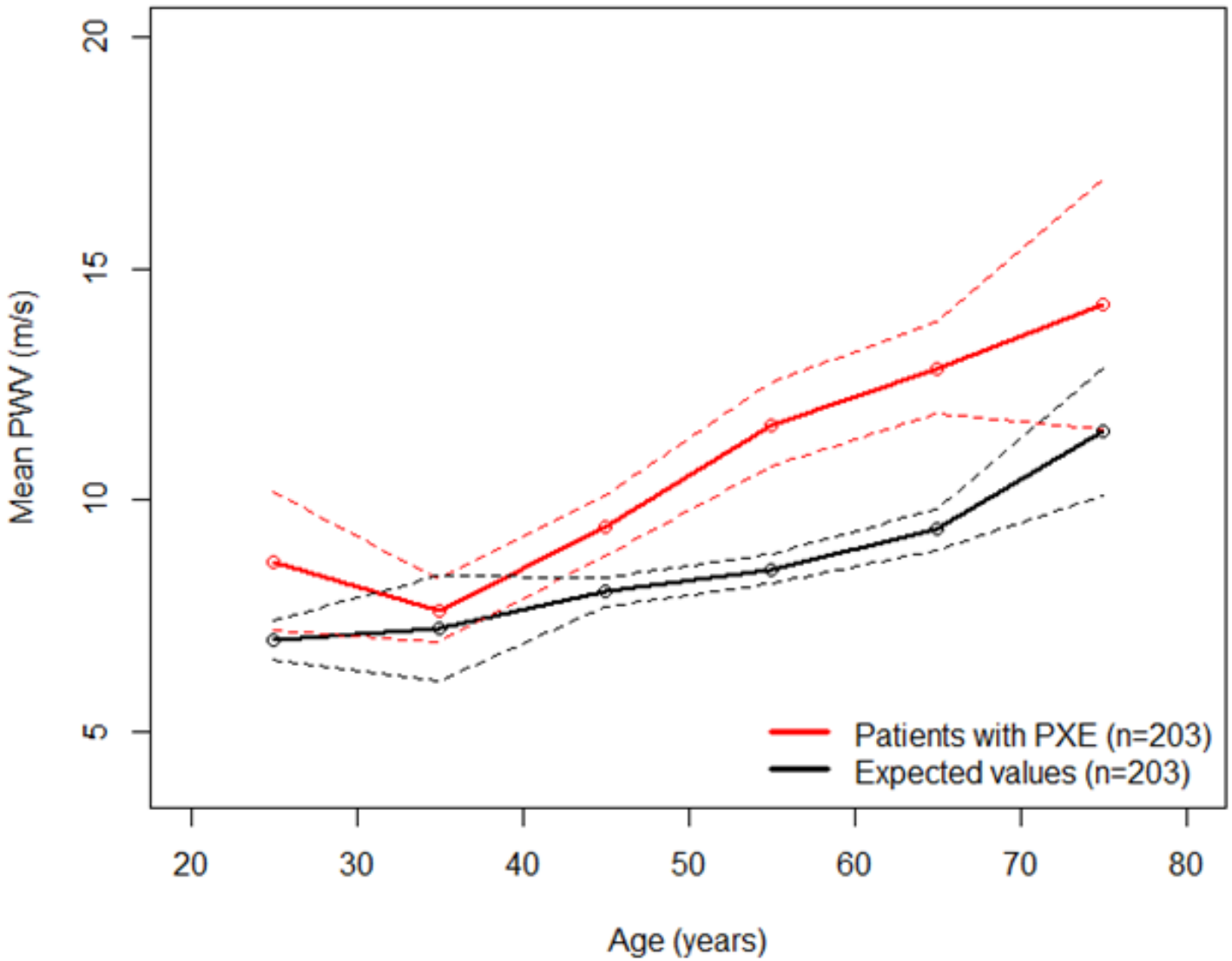

Kranenburg, submitted

Intima-media thickness in PXE vs. DM2

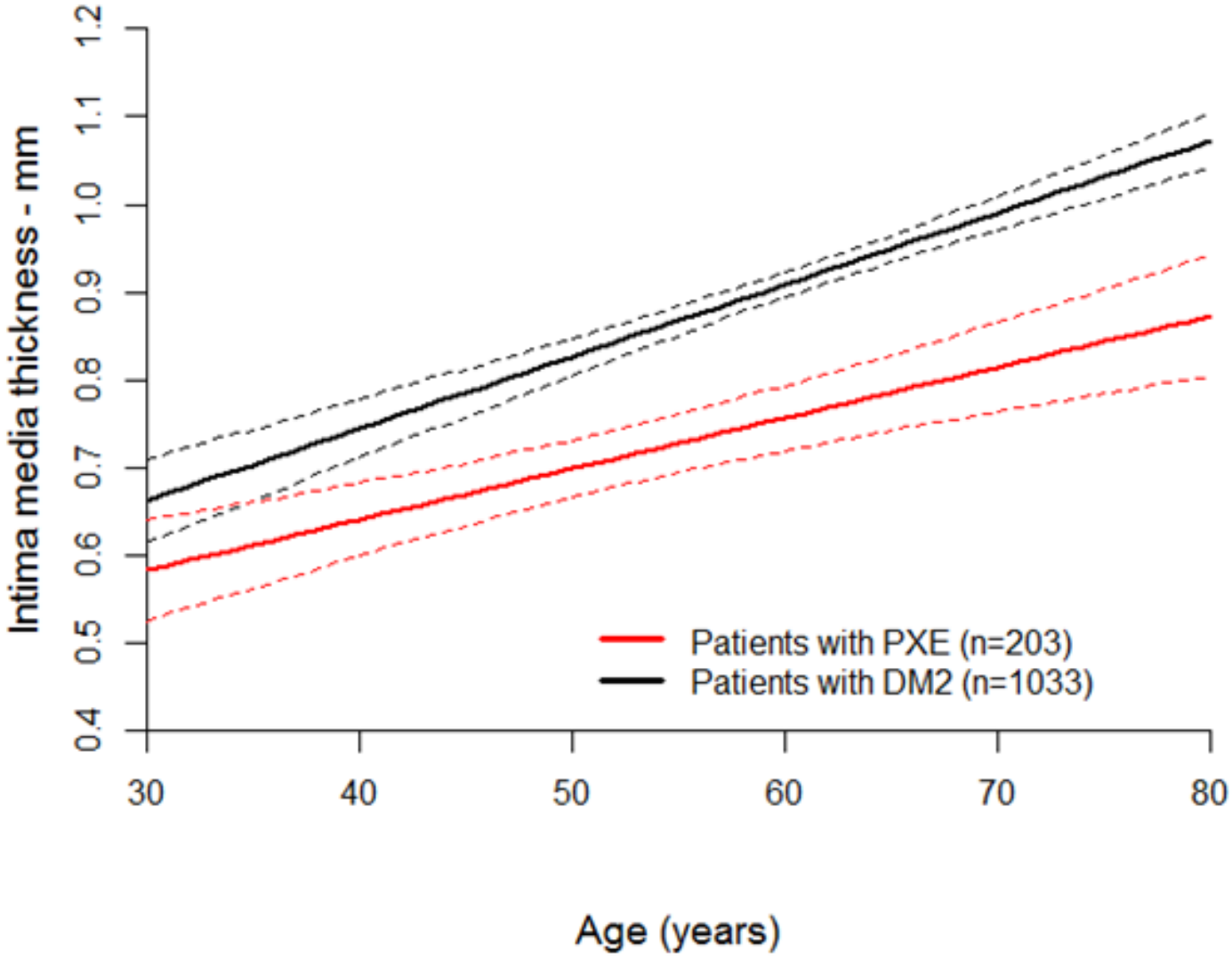

Kranenburg, submitted

Arterial stiffness in PXE vs. DM2

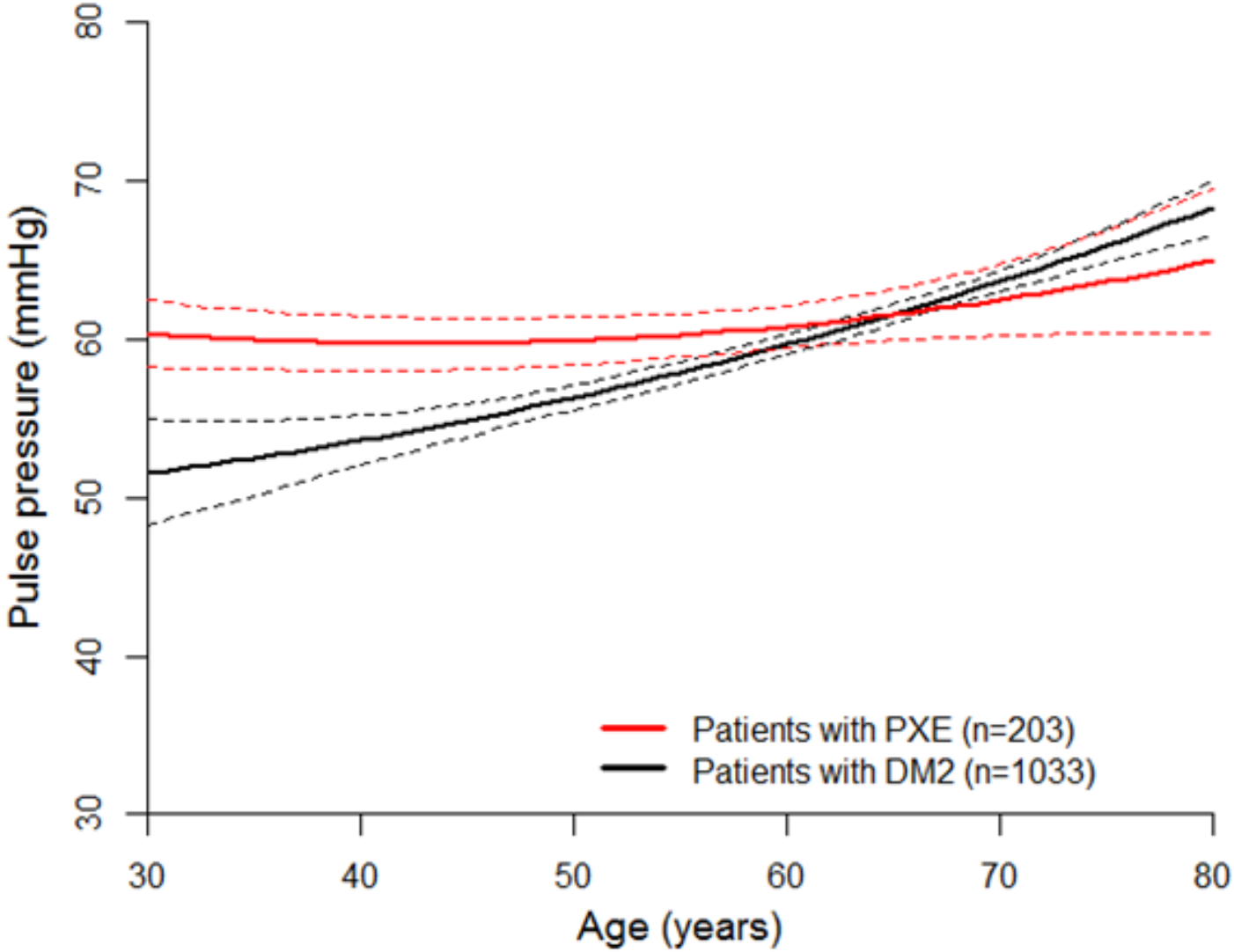

Kranenburg, submitted

Pyrophosphate vs. bisphosphonate

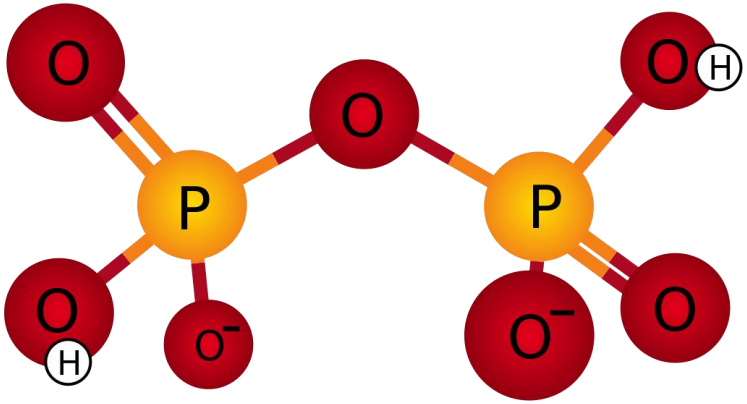

Pyrophosphate

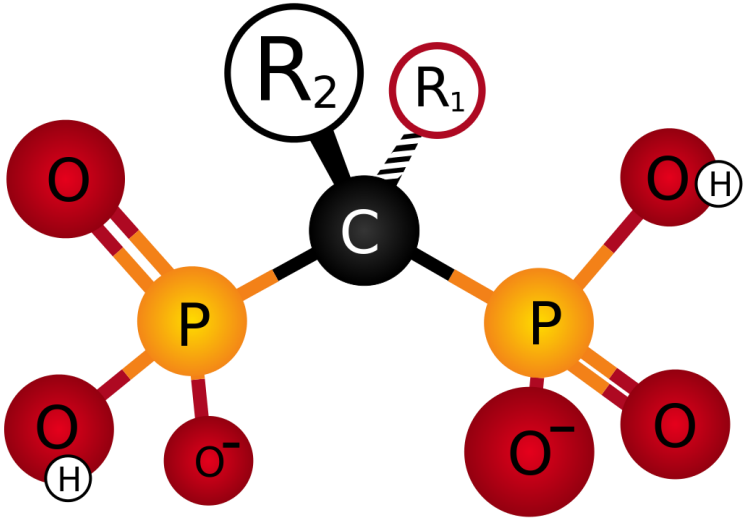

Bisphosphonate

Effects of bisphosphonates in *ABCC6* -/- mice

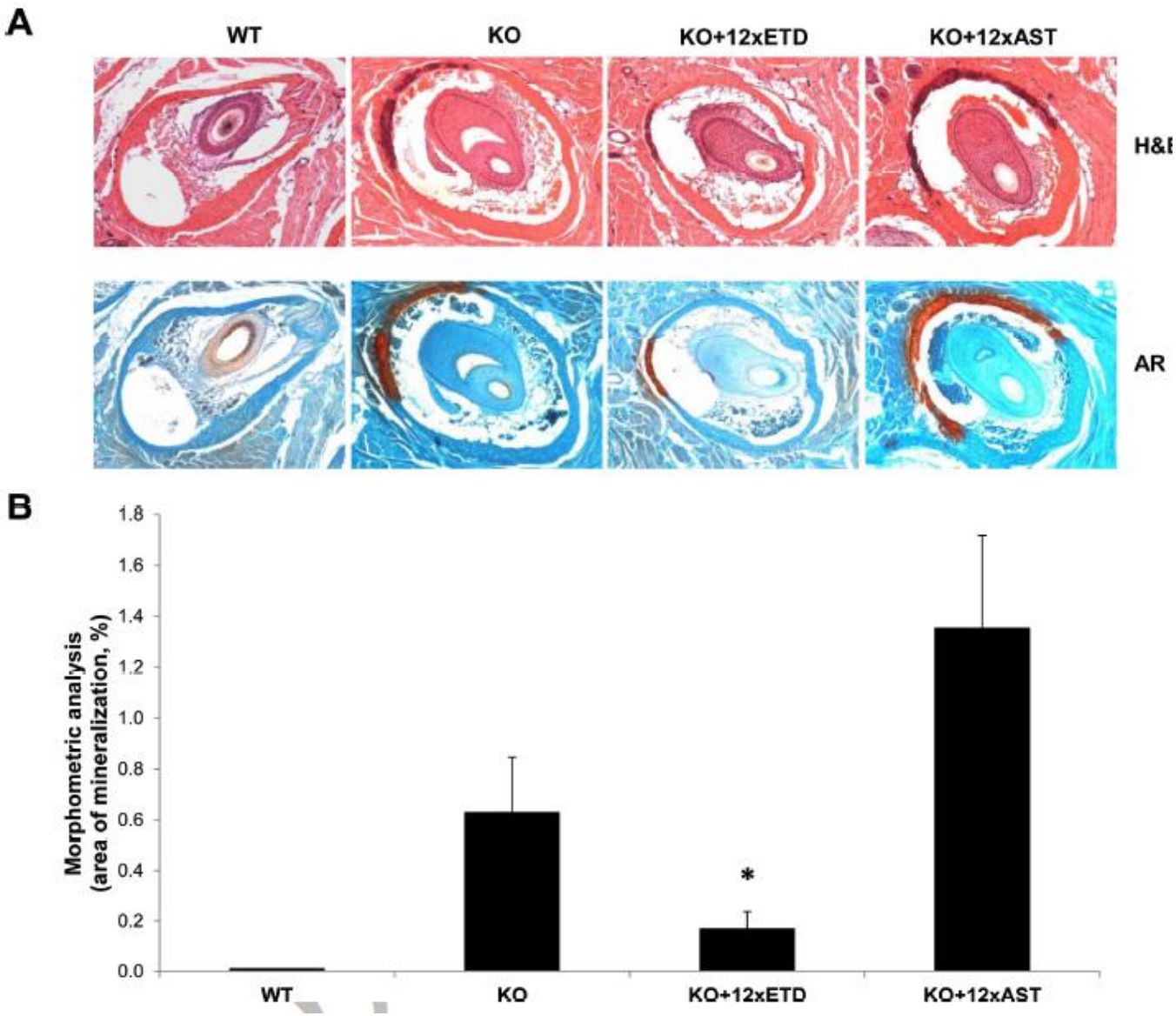

Li, Cell Cycle 2015

Etidronate in *ABCC6* -/- mice

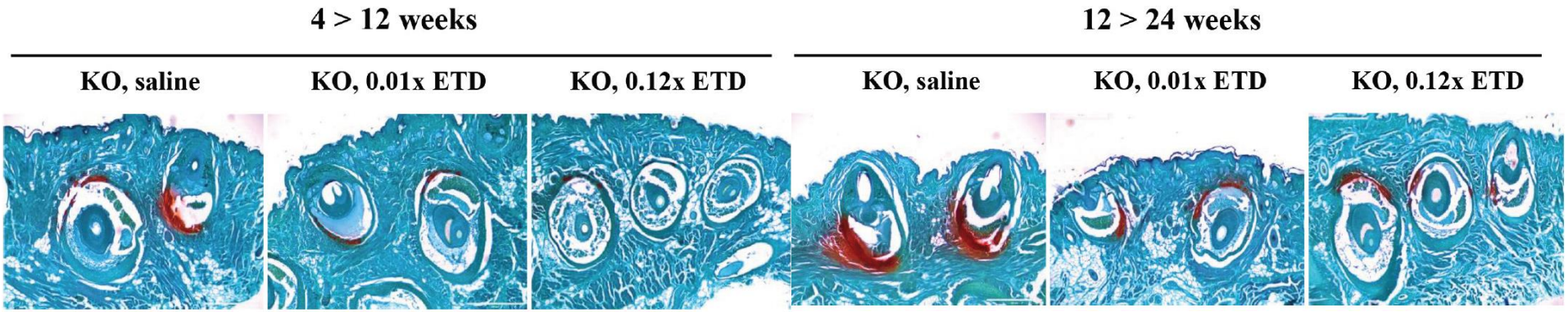

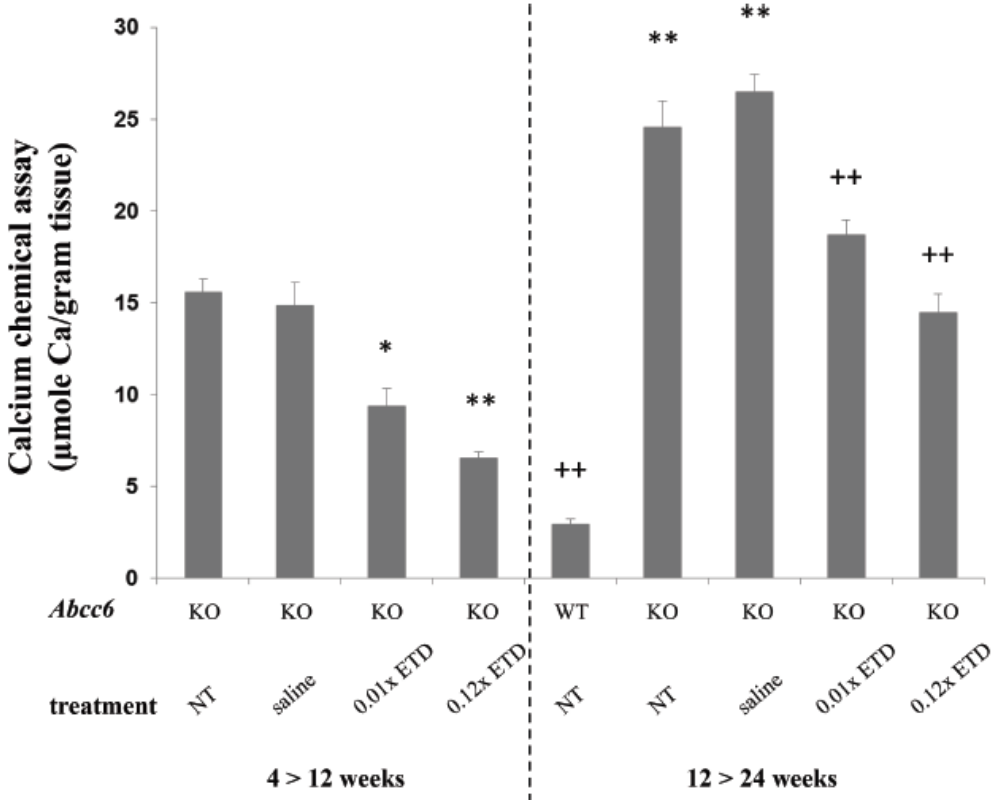

Li, Oncotarget 2016

Etidronate in GACI-syndrome

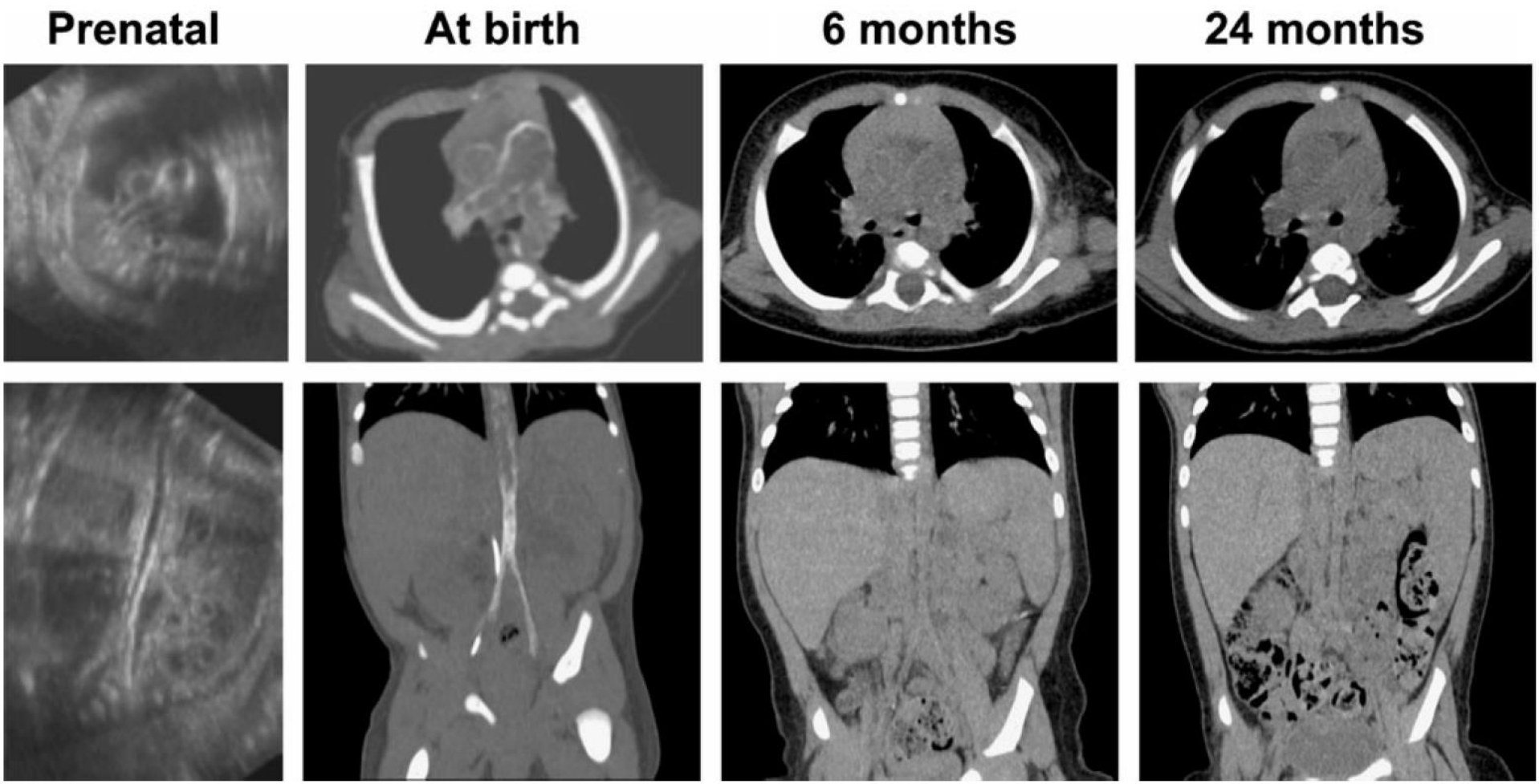

Edouard, Eur J Pediatr 2011

Doel TEMP-studie

Leidt behandeling met de bisfosfonaat etidronaat tot stabilisatie (of afname) van verkalking in PXE?

Opzet TEMP-studie en uitkomsten

- Gerandomiseerd, dubbelblind, placebo-gecontroleerd
- PXE, >18 jaar, vaatverkalking
- Etidronaat (n=74) vs. placebo (n=74) gedurende 12 maanden
- Primaire uitkomst: verandering in $Na^{18}F$-opname in de beenarteriën na 12 maanden behandeling
- Secundaire uitkomsten:
  - CT kalk beenarteriën
  - Oculaire aspecten (neovascularisaties, fundusfotografie, OCT)
  - Intima-media-dikte
  - Vaatstijfheid
  - Botdichtheid
  - Kwaliteit van leven

Study design

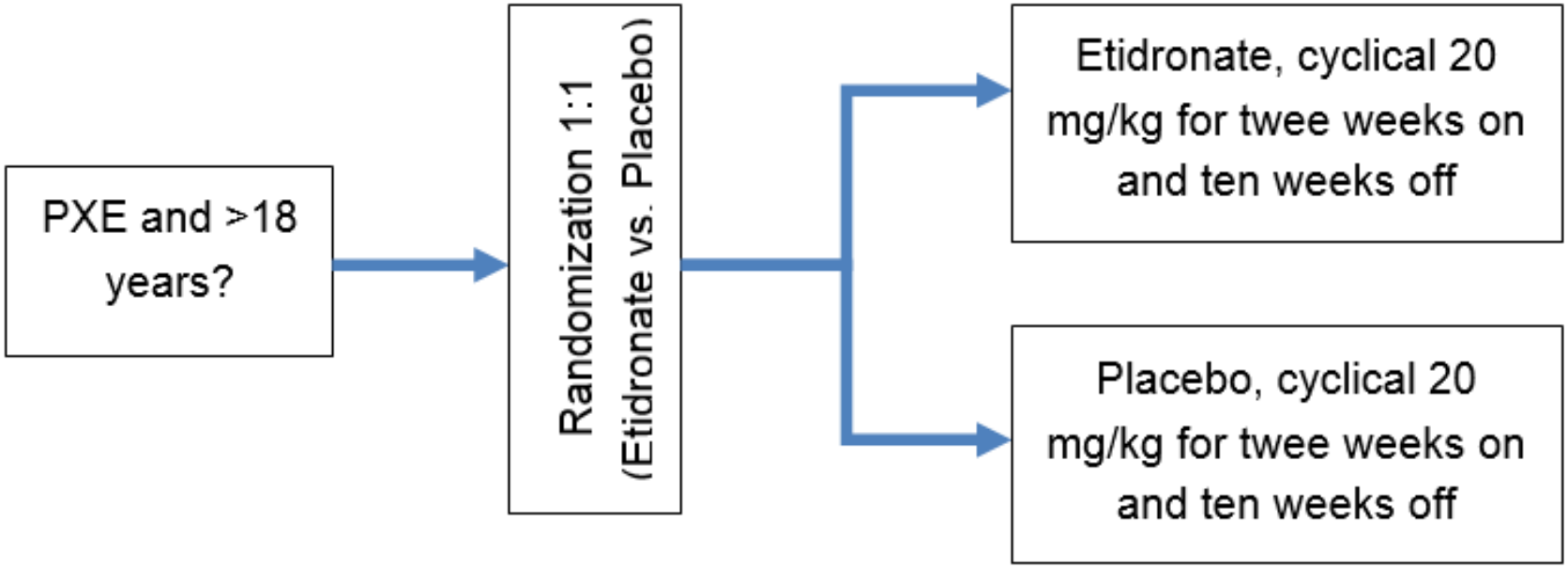

Conclusies

- Residual calcification risk?
- PXE:
  - Vasculaire calcificaties in carotiden, armen, femoro-popliteaal
  - Toegenomen IMT en vaatstijfheid
  - ~15% ischemisch cerebrovasculaire ziekte
  - Tekort aan pyrofosfaat waarschijnlijk oorzaak
  - Binnenkort resultaten of etidronaat vasculaire calcificaties kan voorkomen


Vascular Medicine Utrecht