”Retroperitoneale fibrose/chronische periaortitis:

een geval voor de internist”

Eric van Bommel

albert schweitzer

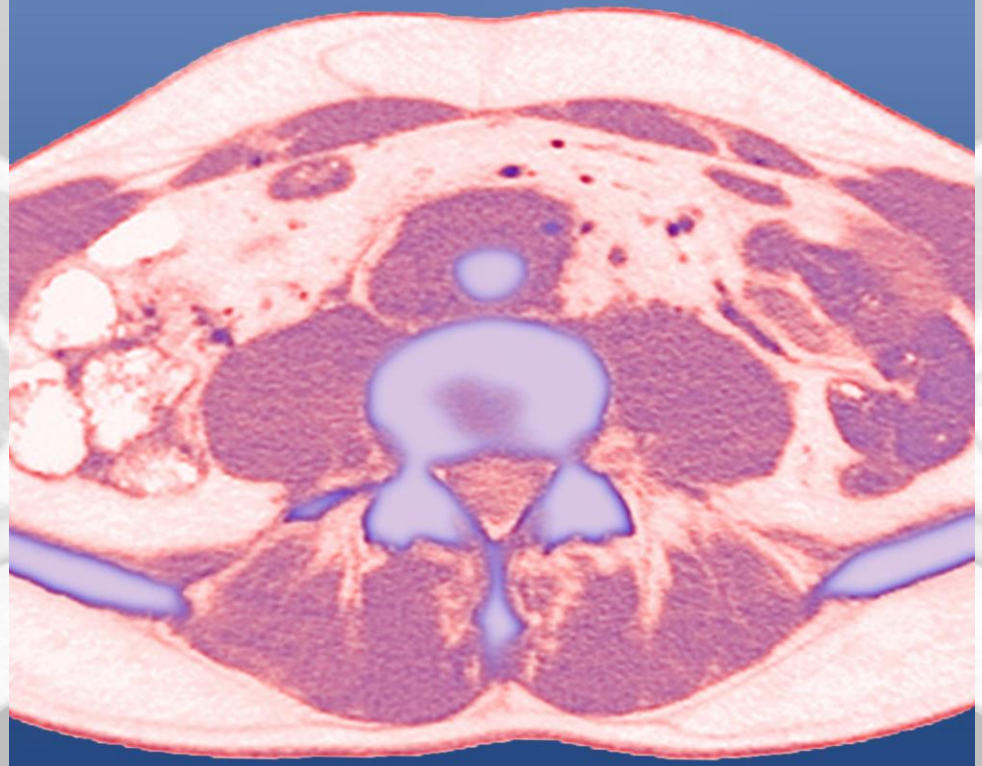

NVIVG Symposium
September 6, 2019

Disclosure belangen spreker:
Eric van Bommel, Albert Schweitzer ZH

(Potentiële) belangenverstrengeling	NEE
Voor bijeenkomst mogelijk relevante relaties:	
Sponsoring of onderzoeksgeld	NVT
Honorarium of andere (financiële) vergoeding	NVT
Aandeelhouder	NVT
Andere relatie, namelijk …	NVT

CardioVasculaire GeneesKunde.nl

RPF | Outline of presentation

- Clinical and radiological presentation of RPF
- How to diagnose this chronic fibro-inflammatory disorder
- Some thoughts about it's pathogenesis
  ►some historical perspective
- Treatment

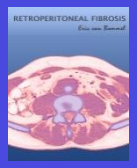

iRPF | Clinical presentation

Still a long time-interval symptoms to diagnosis!

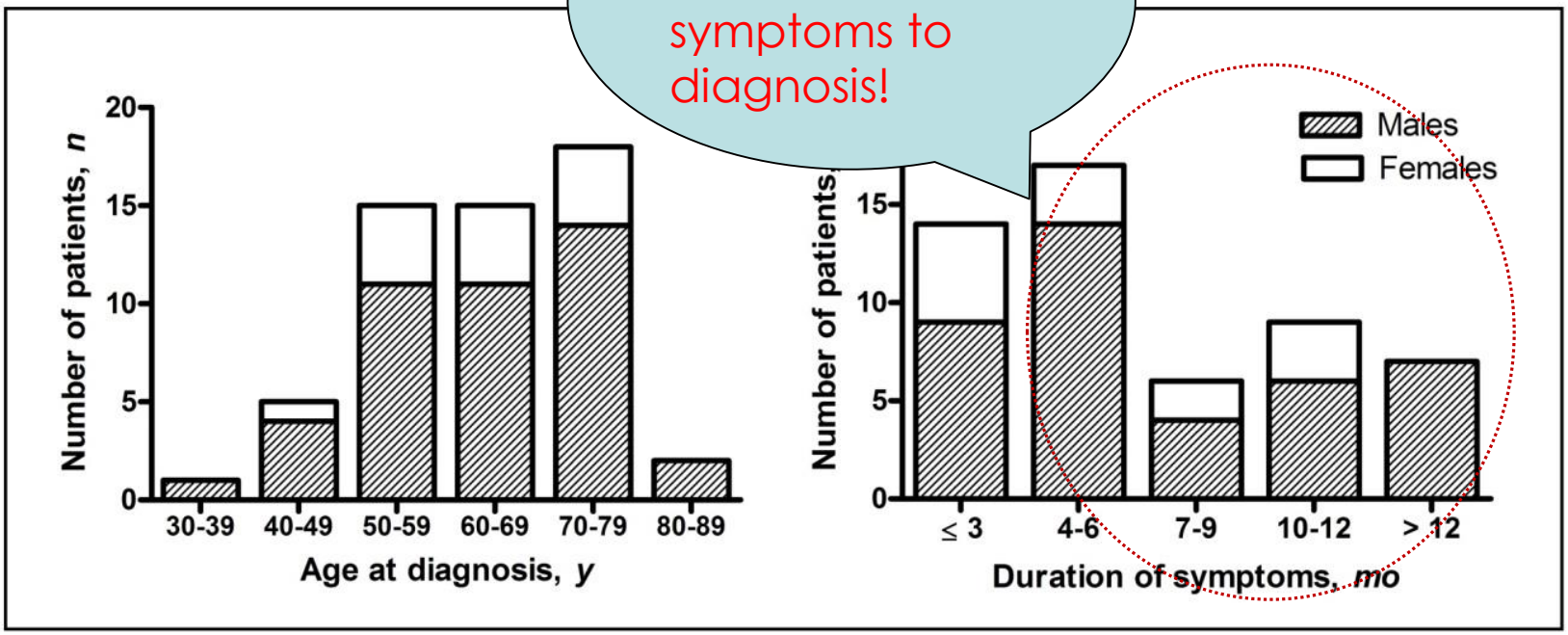

Van Bommel *et al*. Idiopathic retroperitoneal fibrosis: prospective evaluation of incidence and clinicoradiologic presentation. **Medicine (Baltimore) 2009;33(4):193-2-01**

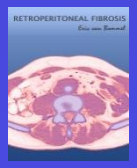

iRPF | Diagnosis

Medical history:

- Lower back, abdominal and/or flank pain
- Constitutional symptoms
- Urinary frequency
- Constipation
- Weightloss
- Testicular pain

Physical examination:

- Hypertension
- Leg edema
- Hydrocèle
- (Fever)

Laboratory examination:

- Elevated APR levels (75%)
- Impaired renal function
- Normocytic anemia
- Hypoalbuminemia
- Elevated IgG4 level

Van Bommel et al. Idiopathic retroperitoneal fibrosis: prospective evaluation of incidence and clinicoradiologic presentation. **Medicine (Baltimore)2009;33:193 201.**

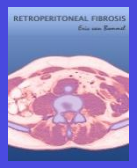

iRPF | Diagnosis

Radiologic examination:

- Ultrasound
- CT scan
- MRI scan
- Nucleair technique
  - SPECT Ga^{67} scan
  - ^{18}FDG-PET scan

Pathological examination:

- CT-guided biopsy
- Surgical biopsy

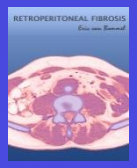

iRPF | CT presentation

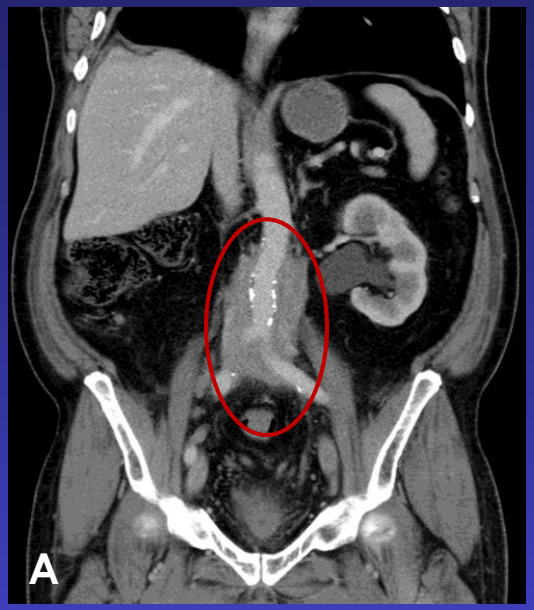

TYPICAL FINDINGS

- Well-defined periaortic soft-tissue mass
- Caudad extension
- No suprarenal expansion
- Retroaortic space relatively spared
- Locoregional lymphadenopathy (< 1 cm)

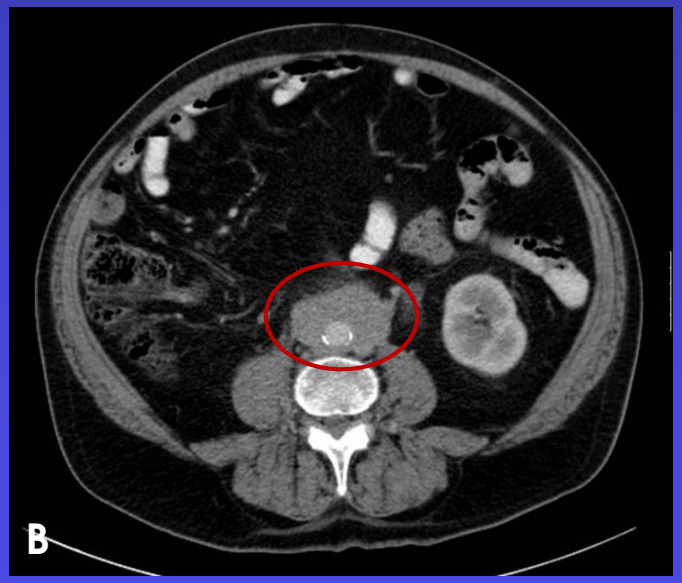

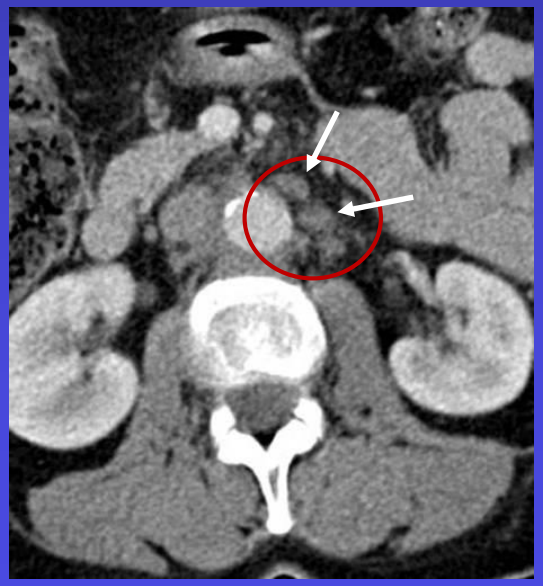

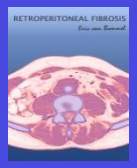

iRPF | CT presentation

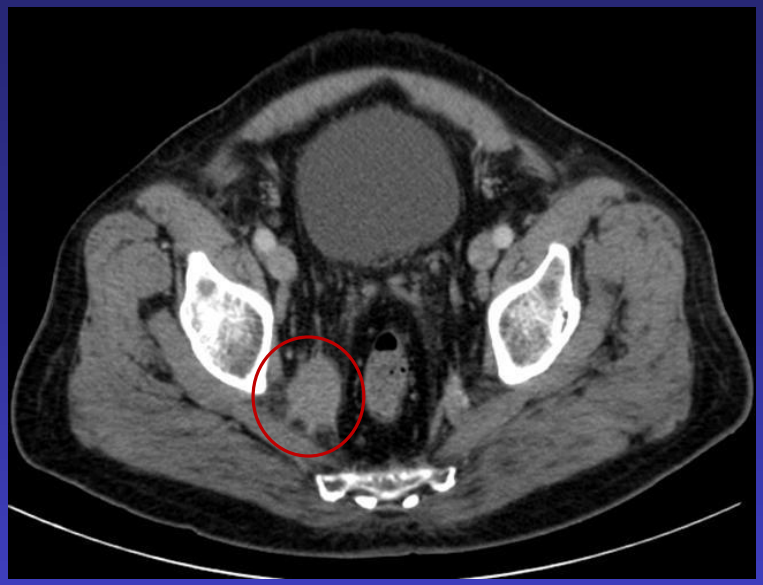

ATYPICAL FINDINGS

- Nodular or irregularly shaped soft-tissue mass
- Atypical localisation
- Suprarenal expansion
- Retroaortic expansion

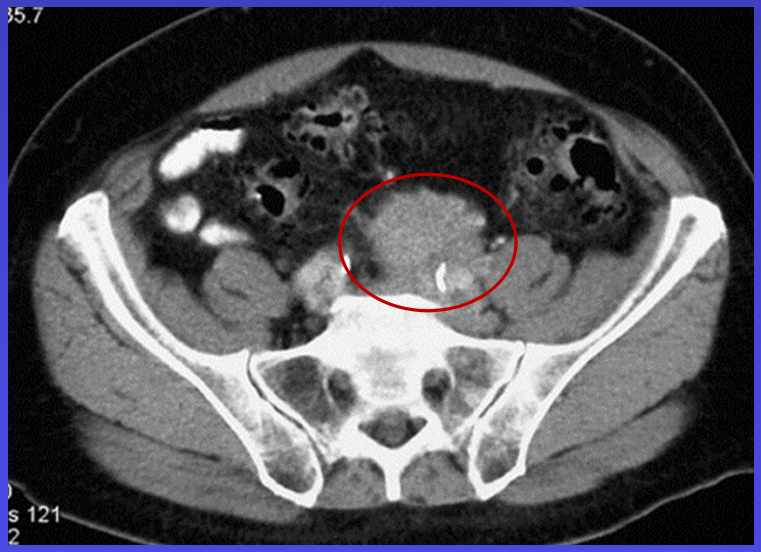

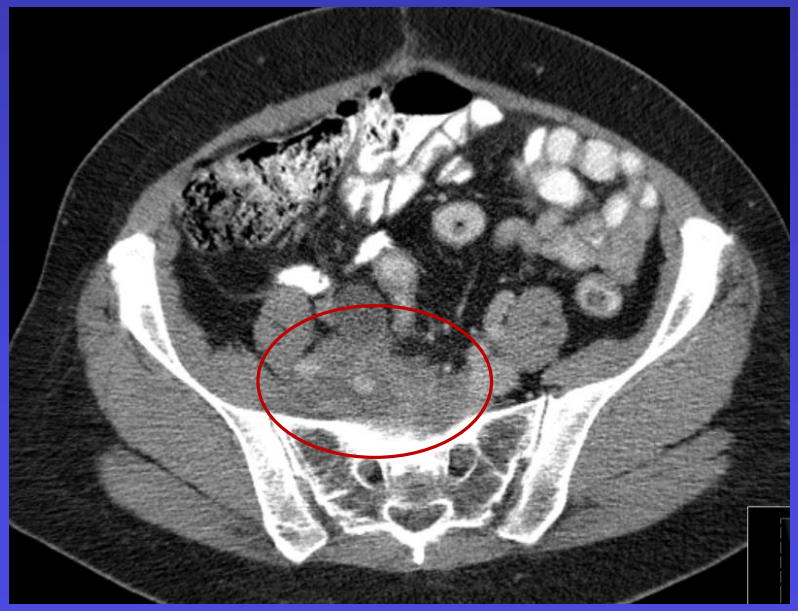

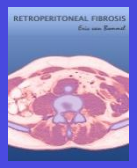

iRPF | The role of biopsy in diagnosing RPF

CT-GUIDED

- Less invasive, less costly
- May visualize safe needle pathway
- May at times be impossible to establish safe route
- Risk of sample error
  - Exuberant desmoplastic reactions

SURGICAL BIOPSY

- Multiple biopsies are considered necessary for a definite diagnosis
  - 'Only then malignancy excluded with (near-)certainty'
- Ureterolysis with lateralisation (+ omental wrappping) more definitive solution for ureteric obstruction

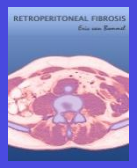

iRPF | The role of biopsy in diagnosing RPF

- Relatively few cases associated with solid cancer have been reported
  - ►TYPICALLY HAVE RADIOLOGICAL ATYPICAL FINDINGS FOR iRPF!
- Differentiating iRPF from malignant lymphoma is the most frequent radiological diagnostic dilemma

Advocated strategy:

- ►**No** previous history of malignancy
  - ►Notably UCC, breast cancer, bowel cancer
- ►**No** suspected findings after careful search for (occult) malignancy
  - ►Physical examination, abdominal CT, chest radiograph, (chest CT, mammography, colonoscopy, PET scan)
- ►**No** radiological **ATYPICAL** findings for iRPF

►Biopsy not required

Van Bommel. Retroperitoneal fibrosis. **Neth J Med. 2002;** Vaglio A *et al*. Retroperitoneal fibrosis. **Lancet 2006.** Van Bommel *et al.* Idiopathic retroperitoneal fibrosis mimicking malignant lymphoma. **Path Int 2011.**

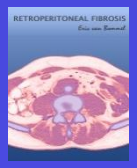

iRPF | Histopathology

Chronic fibrosing, T-cell mediated inflammatory reaction

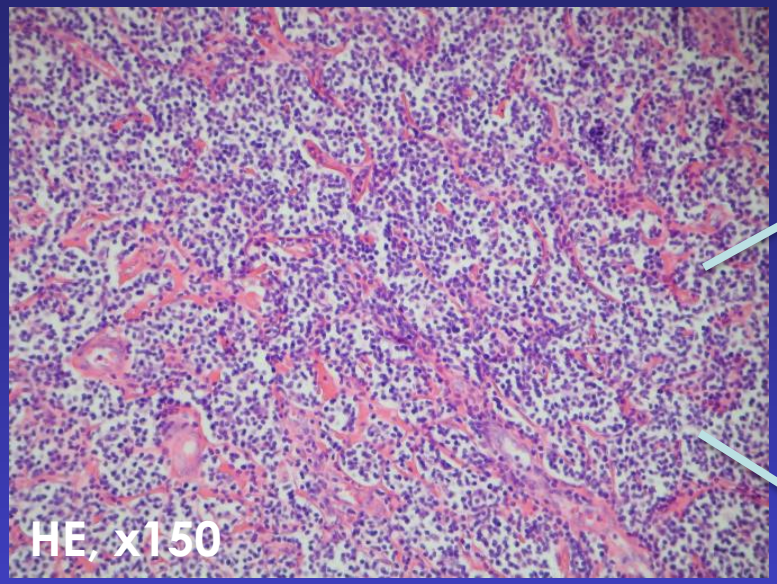

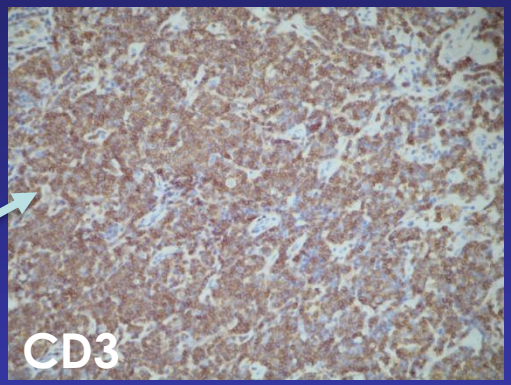

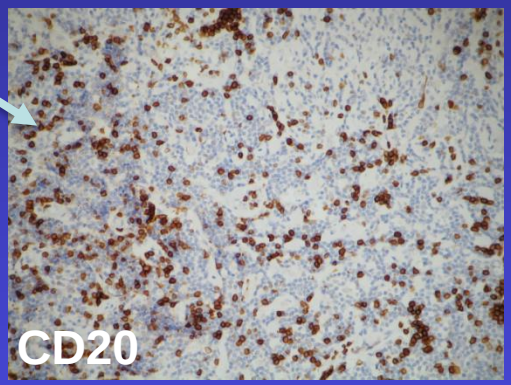

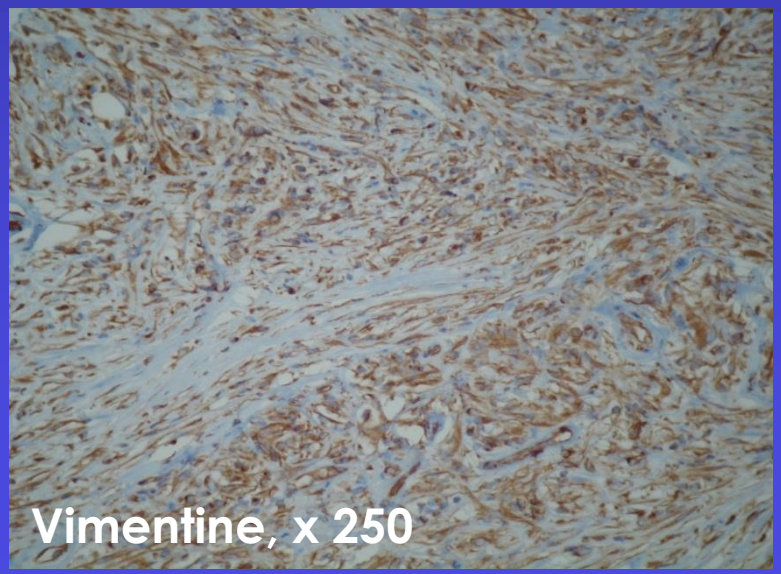

Sclerotic tissue

- FibroblastsType 1 collagen

Inflammatory infiltrate

- Lymphocytes
- Plasmacells
- Eosinophils
- Nodular or diffuse pattern

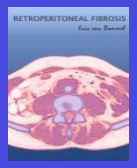

iRPF | Regulatory T cells predominate

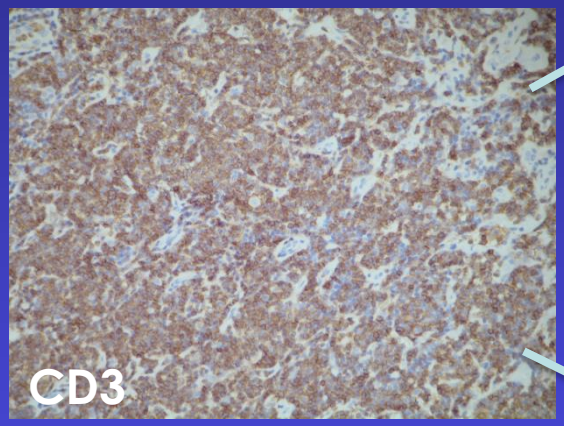

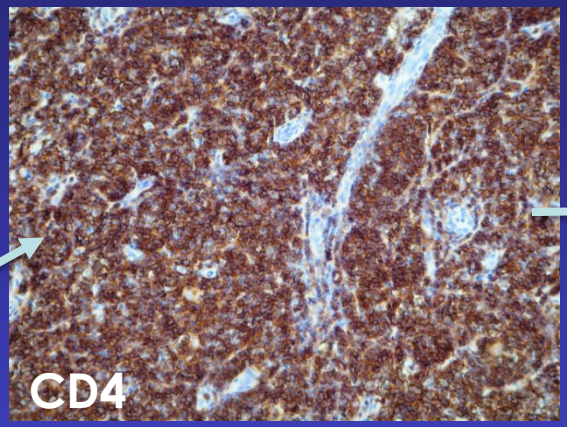

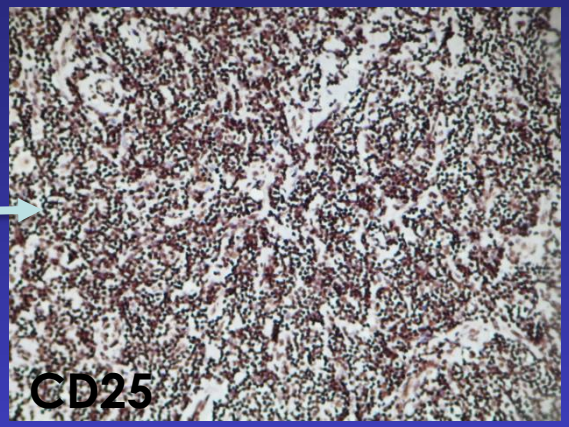

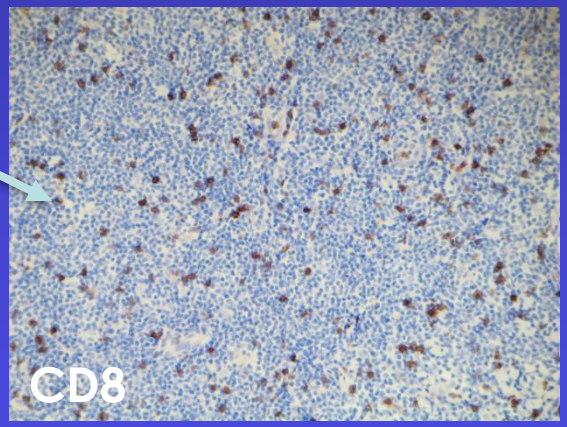

Infiltrate primarily consisting of T-helper lymphocytes expressing the IL-1a receptor chain

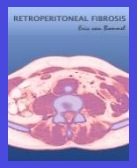

van Bommel *et al*. **Pathol Int. 2011 Nov;61(11):672-676.**

RPF | Pathogenesis

Secondary retroperitoneal fibrosis:

- **'Direct' causes leading to chronic retroperitoneal inflammation**
  - post-pancreatitis, post-surgery, trauma, radiotherapy, infection
- **Secondary to malignancy**
  - Paraneoplastic/desmoplastic reaction
  - Small bowel NET ('carcinoid fibrosis')
- **Drug-related**
  - Only firm evidence for ergotalkaloids (methysergide, bromocriptine)
- **Other diseases**
  - Histiocytosis, Erdheim-Chester disease

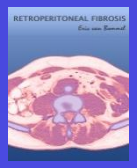

RPF | Pathogenesis

Idiopathic retroperitoneal fibrosis:

- **Auto-immune mechanisms**
  - Systemic vs. local perivascular reaction?
- **Genetic or familial factors**
- **Environmental factor**
  - Asbestosis, smoking

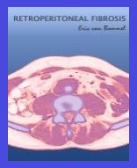

iRPF | Pathogenesis

systemic disorder vs. localised process

- Raised ESR/CRP; constitutional symptoms
- Co-existent auto-immune disorders/phenomenon
- Vasculitis sometimes observed in tissue samples
- Additional fibrosis at other sites
  - e.g., orbital pseudotumor, Riedel's thyroiditis

} SYSTEMIC DISEASE ?

- Presumed iRPF may be **LOCAL** complication of severe atherosclerosis
  - ►Many patients with iRPF have a significantly increased CV risk profile
  - ►Frequent co-existence of ectatic/aneurysmal Ao diameter

Van Bommel *et al*. Idiopathic retroperitoneal fibrosis: prospective evaluation of incidence and clinicoradiologic presentation. **Medicine (Baltimore) 2009;33(4):193-2-01**

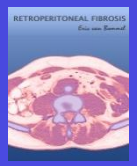

iRPF | Pathogenesis, a hypothesis

Mitchinson & Parums, 70s/80s

The pathology of idiopathic retroperitoneal fibrosis. *J Clin Pathol.* 1970
Aortic disease in idiopathic retroperitoneal and mediastinal fibrosis. *J Clin Pathol.* 1972
Computed tomographic observations in periaortitis: a hypothesis. *Clin Radiol*. 1984
Chronic coronary periarteritis in two patients with chronic periaortitis. *J Clin Pathol*. 1984
The localisation of immunoglobulin in chronic periaortitis. *Atherosclerosis*. 1986
Chronic periaortitis and periarteritis. *Histopathology*. 1984
Retroperitoneal fibrosis revisited. *Arch Pathol Lab Med*. 1986
Characterization of inflammatory cells in a patient with chronic periaortitis. *Am J Cardiovasc Pathol*. 1990
Serum antibodies to oxidized low-density lipoprotein and ceroid in chronic periaortitis. *Arch Pathol Lab Med*. 1990

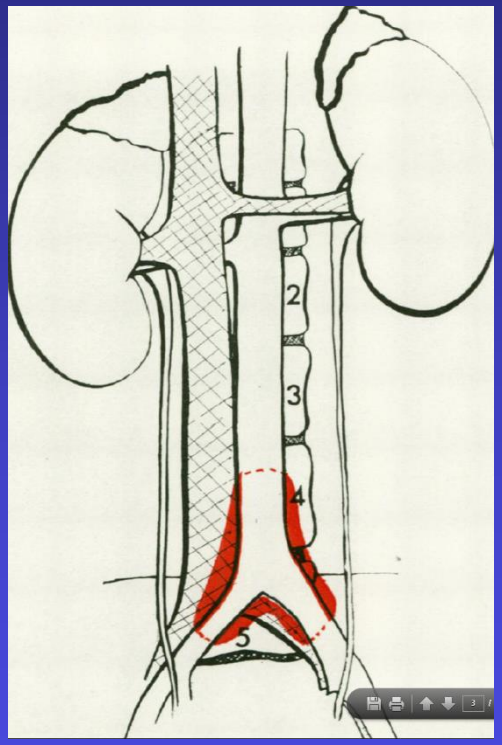

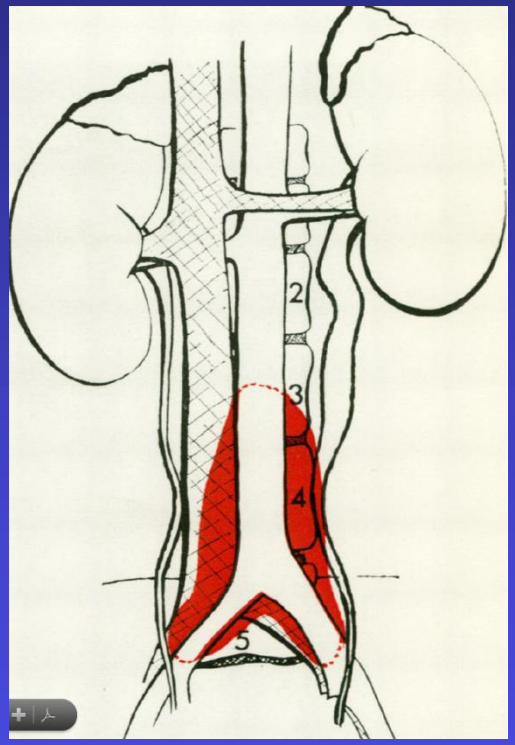

"The present study suggests that damage to the aortic wall might be the underlying abnormality. The adventitial inflammation and spreading fibrosis might be secondary to aortitis, such as by leakage of some allergen (lipoprotein?) through the damaged wall." ***Mitchinson 1970***

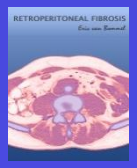

iRPF | Pathogenesis, a hypothesis

Mitchinson & Parums, 70s/80s

The pathology of idiopathic retroperitoneal fibrosis. *J Clin Pathol.* 1970
Aortic disease in idiopathic retroperitoneal and mediastinal fibrosis. *J Clin Pathol.* 1972
Computed tomographic observations in periaortitis: a hypothesis. *Clin Radiol*. 1984
Chronic coronary periarteritis in two patients with chronic periaortitis. *J Clin Pathol*. 1984
The localisation of immunoglobulin in chronic periaortitis. *Atherosclerosis*. 1986
Chronic periaortitis and periarteritis. *Histopathology*. 1984
Retroperitoneal fibrosis revisited. *Arch Pathol Lab Med*. 1986
Characterization of inflammatory cells in a patient with chronic periaortitis. *Am J Cardiovasc Pathol*. 1990
Serum antibodies to oxidized low-density lipoprotein and ceroid in chronic periaortitis. *Arch Pathol Lab Med*. 1990

PATHOLOGY FINDINGS, *n* = 40

- Predominantly periaortic with caudad extension to iliac arteries
- Often severe atherosclerosis
- Protrusion of atherosclerotic debris through attenuated media into the fibrotic adventitia

"The present study suggests that damage to the aortic wall might be the underlying abnormality. The adventitial inflammation and spreading fibrosis might be secondary to aortitis, such as by leakage of some allergen (lipoprotein?) through the damaged wall." ***Mitchinson 1970***

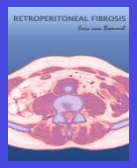

iRPF | Pathogenesis, a hypothesis

Parums & Mitchinson, 70s/80s

IDIOPATHIC RETROPERITONEAL FIBROSIS
INFLAMMATORY AORTIC ANEURYSM
PERIANEURYSMAL FIBROSIS
MEDIASTINAL FIBROSIS

It is therefore preferable to group them all together as 'chronic periaortitis'

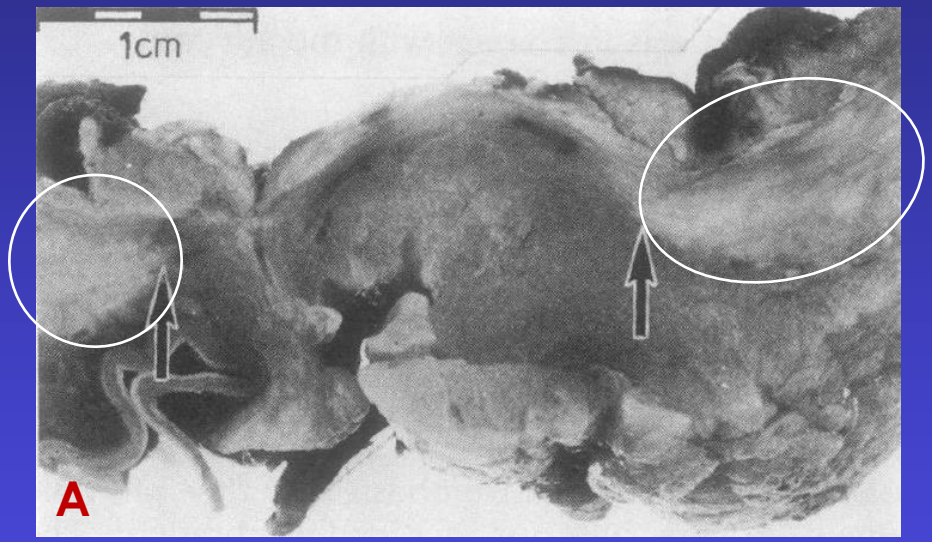

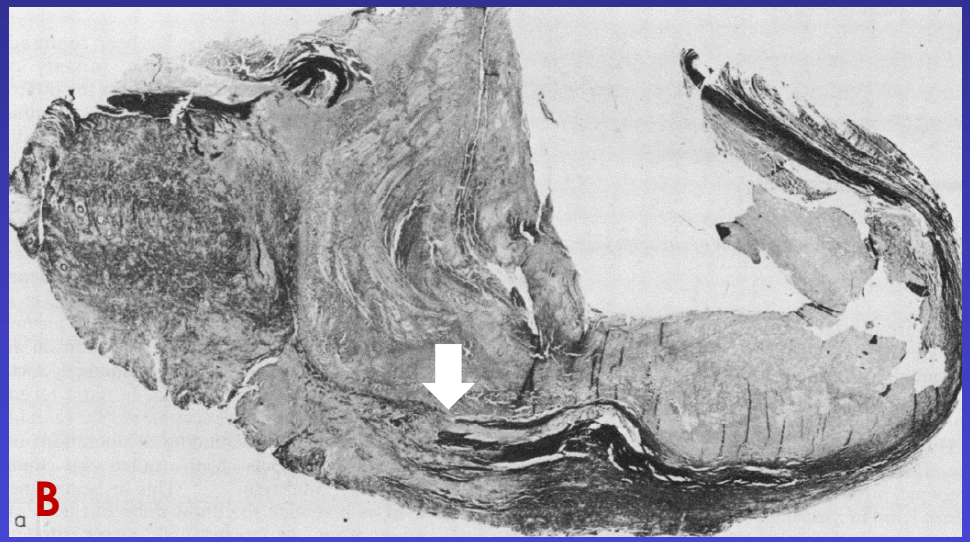

A. Histological features of all variants identical: *adventitial fibrosis and chronic inflammation, primarily lymphocytes and plasma cells.*

B. The atheromatous plaque acts as an immunologically 'priviliged site': *the lipoprotein allergen is sequestered from the immune response unless the media is breached.*

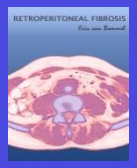

iRPF | Pathogenesis, a hypothesis

Serum antibodies to oxidized low-density lipoprotein and ceroid in chronic periaortitis.
Parums & Mitchinson, *Arch Pathol Lab Med*. 1990

- ►**Ceroid = insoluble polymer of oxidized lipoprotein**
- ►**Can artificially be produced**
- ►**Ceroid found in all atherosclerotic plaques**
- ►**Immunoglobulin, predominantly IgG, found to localize to ceroid in plaques**

DETECTION OF ANTIBODIES TO CEROID and OXLDL IN SERUM SAMPLES FROM 5 GROUPS (*N*=20)

CPA: IAAA, n=12/ iRPF, n=8; mean age 62.7 yr
scCPA: cases identified on routine necropsy; mean age 70.5 yr
IHD: unselected pts with CAD from cardiology outpatient dept; mean age 59.7 yr
Elderly controls: necropsy cases with minimal atherosclerosis/no CPA; mean age 66.7 yr
Normal controls: young healthy volunteers; mean age 23 yr

The results for each patient with chronic periaortitis, subclinical chronic periaortitis, and ischemic heart disease, and for elderly controls, to the antigens' low-density lipoprotein (LDL), *oxidized LDL, artificial ceroid, and ceroid. The bars represent the mean ± 2 SDs optical density* (OD; 492 nm) in the young control group. A positive result was considered to be represented by a mean OD more than 2 SDs above the mean of the young control group.

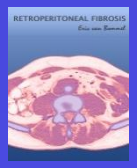

iRPF | Pathogenesis, a hypothesis

Serum antibodies to oxidized low-density lipoprotein and ceroid in chronic periaortitis.
Parums & Mitchinson, *Arch Pathol Lab Med*. 1990

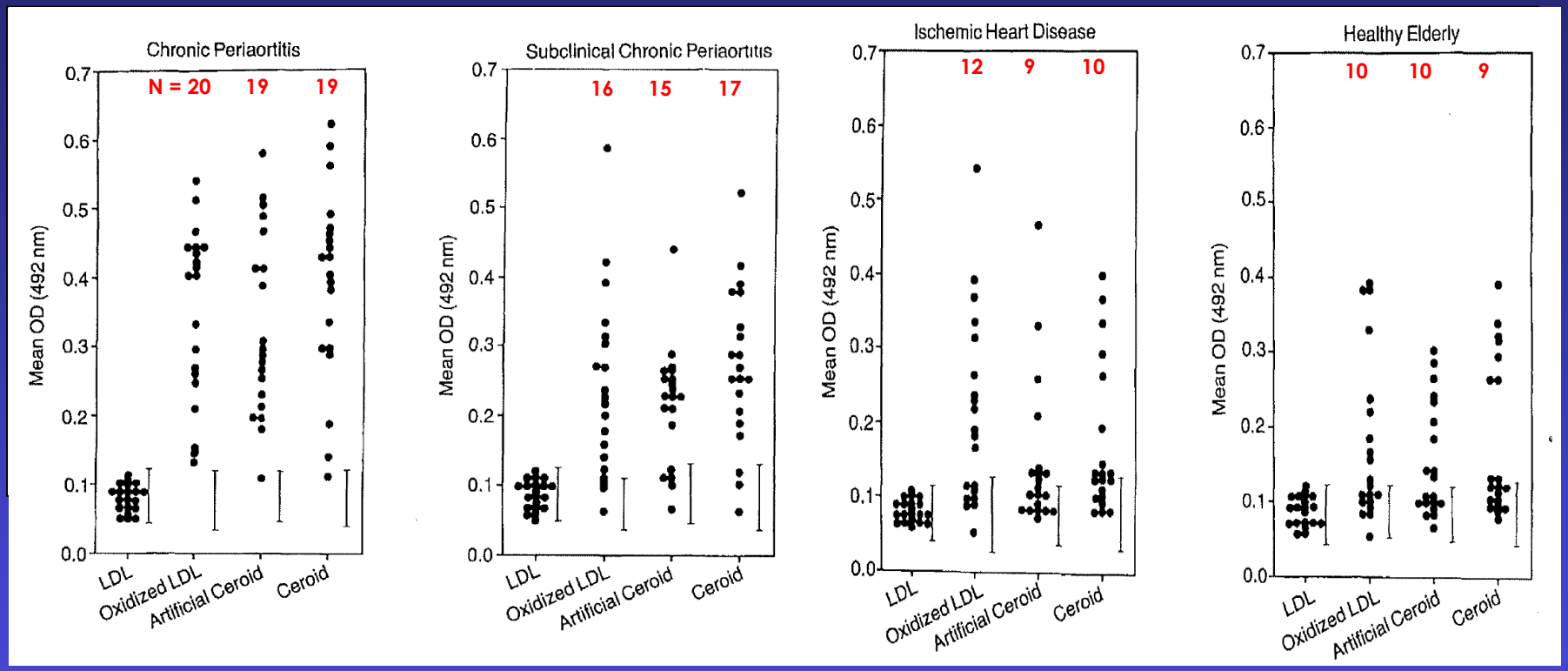

The results for each patient with chronic periaortitis, subclinical chronic periaortitis, and ischemic heart disease, and for elderly controls, to the antigens' low-density lipoprotein (LDL), *oxidized LDL, artificial ceroid, and ceroid. The bars represent the mean ± 2 SDs optical density* (OD; 492 nm) in the young control group. A positive result was considered to be represented by a mean OD more than 2 SDs above the mean of the young control group.

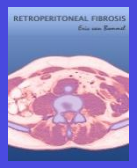

iRPF | Pathogenesis, a hypothesis

Serum antibodies to oxidized low-density lipoprotein and ceroid in chronic periaortitis.
Parums & Mitchinson, *Arch Pathol Lab Med*. 1990

"chronic periaortitis is accompanied by auto-allergy to ceroid, which is at least partly composed of oxLDL within the atherosclerotic plaque"

The results for each patient with chronic periaortitis, subclinical chronic periaortitis, and ischemic heart disease, and for elderly controls, to the antigens' low-density lipoprotein (LDL), *oxidized LDL, artificial ceroid, and ceroid. The bars represent the mean ± 2 SDs optical density* (OD; 492 nm) in the young control group. A positive result was considered to be represented by a mean OD more than 2 SDs above the mean of the young control group.

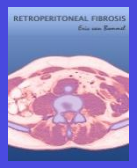

iRPF | iRPF = chronic peri-aortitis

Influence of aneurysm exclusion on course of CPA

	Open surgical repair	EVAR	*P*-value
Regression of PAF, n (%)	179/208 (86%)	31/52 (60%)	< 0.001
Complete regression, n (%)	109/208 (52%)	7/52 (14%)	< 0.001
Resolution of ureteral obstruction, n (%)	72/97 (73%)	9/19 (47%)	0.02

►Exclusion of aneurysm may 'cure' CPA

Van Bommel *et al.* Persistent chronic peri-aortitis ('inflammatory aneurysm') after abdominal aortic aneurysm repair: systematic review of the literature. **Vasc Med 2008;13:293-303**

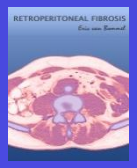

iRPF | Pathogenesis

Local perivascular reaction vs systemic disease

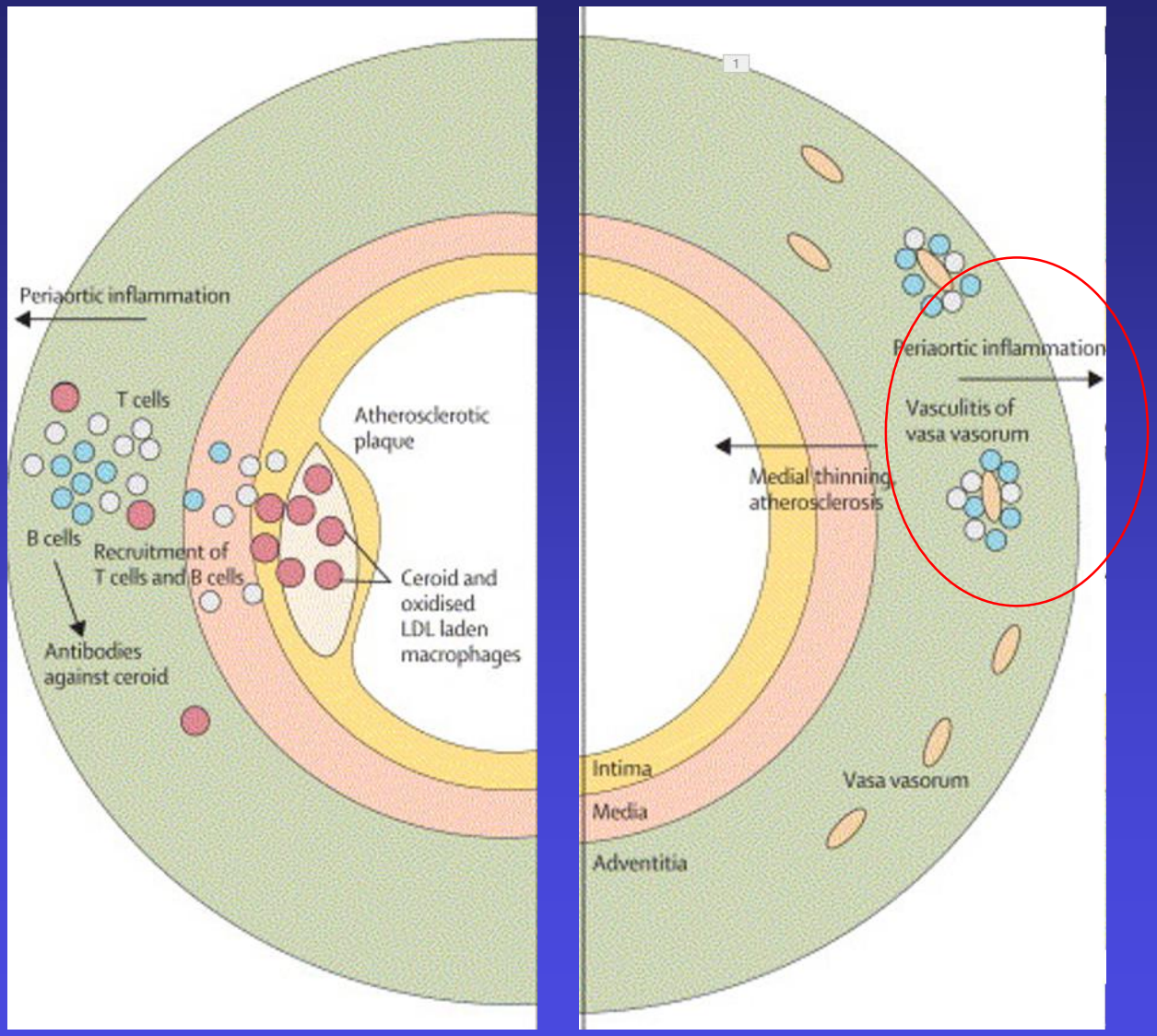

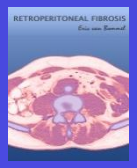

Mitchinson MJ. Retroperitoneal fibrosis revisited. **Arch Path Lab Med 1986;** Parums DV. Spectrum of chronic peri-aortitis. **Histopathology 1990;** Parums DV *et al*. Characterisation of inflammatory cells associated with idiopathic retroperitoneal fibrosis. **Br J Urol 1991;** Vaglio A *et al*. Retroperitoneal fibrosis. **Lancet 2006**

iRPF | CPA and systemic vasculitis

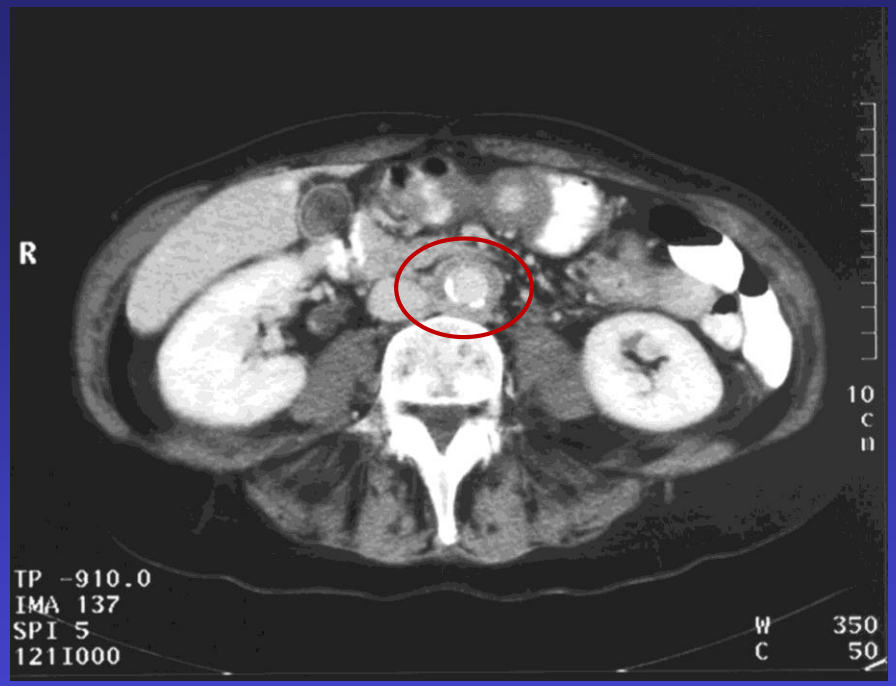

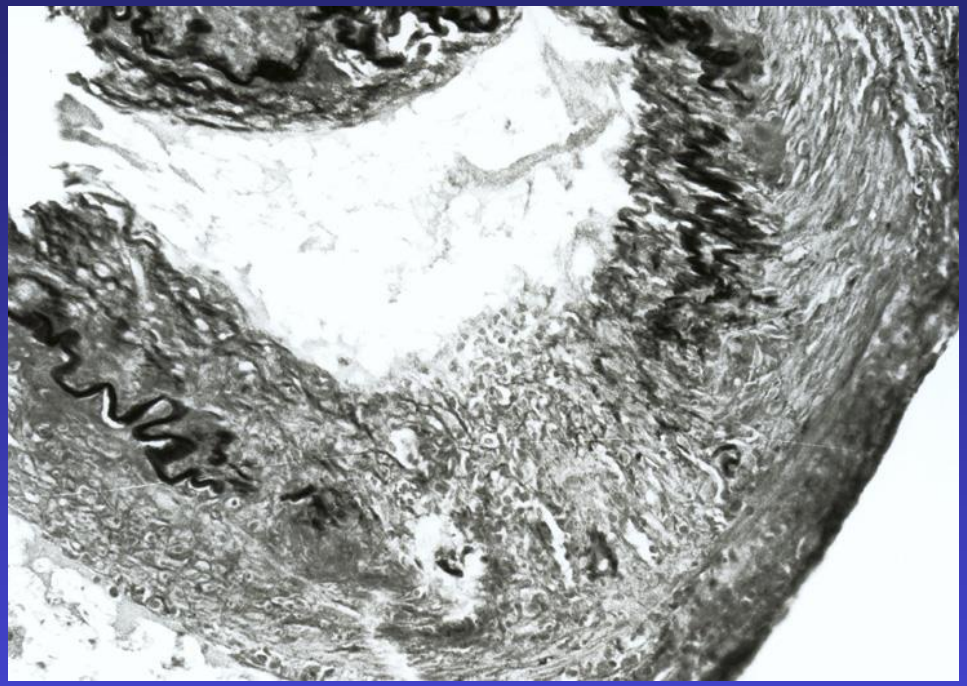

Van Bommel *et al*. Retroperitoneal fibrosis and p-ANCA-associated polyarteritis nodosa: coincidental or common etiology? **Eur J Intern Med. 2002 Sep;13(6):392.**

►To date, 9 additional case reports of patients with iRPF and ANCA-positive vasculitis

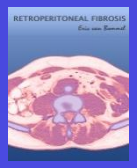

iRPF | genetics suggesting AID

Martorana *et al*, J Allergy Clin Immunol. 2018

STUDY

Patients with idiopathic RPF, *n*=308 from Italian (*Parma, Milan, Firenze*) and Dutch (*Dordrecht*) cohort

Non-affected control subjects, *n*=2.443

Genotyping with Immunochip array, a platform with dense coverage of variants associated with AID (403,081 genetic variants).

RESULTS

►Genome-wide significant associations with class II HLA alleles, HLA-DRB1*0301 and HLA-DQB1*0201, but also with class I alleles.

►When conditioned on HLA-DRB1*0301 alleles, no independent associations were detected.

►Association with **HLA-DRB1*03** translated into the presence of **Arg74** in the peptide-binding pocket of HLA DRb.

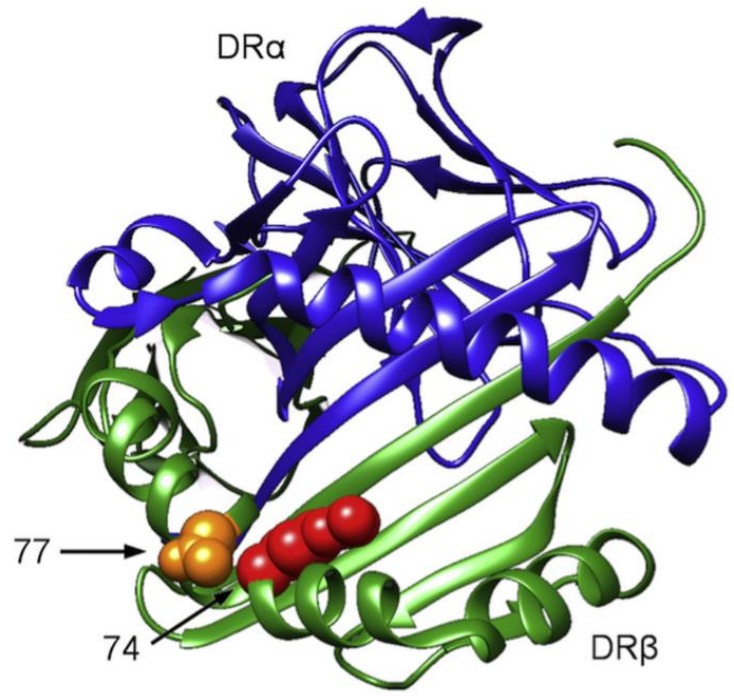

FIG 2. Three-dimensional ribbon representation of the HLA-DR molecule. Amino acid positions associated with idiopathic RPF are highlighted. This figure was prepared by using UCSF Chimera.

"Findings suggest that idiopathic RPF is an autoimmune disease and invoke the presence of a disease-triggering autoantigen."

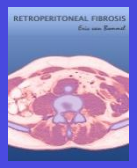

iRPF | genetics suggesting AID

Martorana *et al*, J Allergy Clin Immunol. 2018

- HLA-DRB1*03 marker of autoimmunity: associated with SLE, type 1 diabetes, and myasthenia gravis
- Arg74 also associated with autoimmunity

"Findings suggest that idiopathic RPF is an autoimmune disease and invoke the presence of a disease-triggering autoantigen."

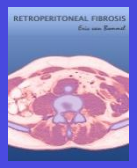

iRPF | iRPF or IgG4-RD?

71-YR-OLD MALE PATIENT

Medical history:
- 1962 Tonsillectomy
- 2003 Extirpation parotid glands
- 2005(3) iRPF, good response on CS treatment (18 mo) with SR/CR RP mass

→ **2016(11)**
Recurrent abdominal pain, constipation

Lab results: ESR 97 mm/h; CRP 24 mg/L; Creatinine 104 µmol/L; sIgG4 2,27 g/L

CT abdomen: soft-tissue mass paraaortic/parailiacal with pelvic extension

^{18}FDG-PET scan: FDG avidity RP mass, pancreas, hilar and mediastinal lymph nodes, parotic glands

Histopathological revision tissue samples 2003: **COMPATIBLE WITH IgG4-RD**

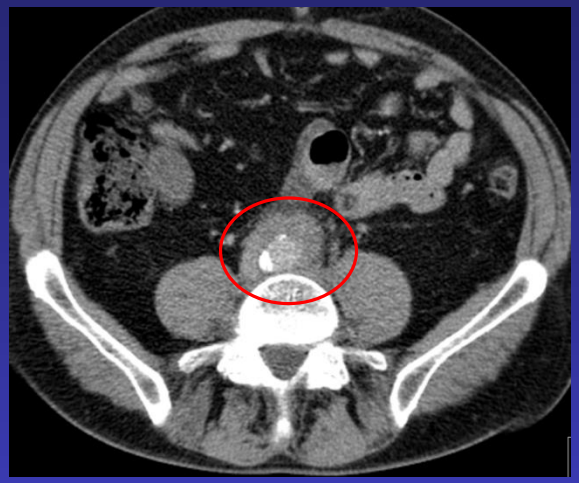

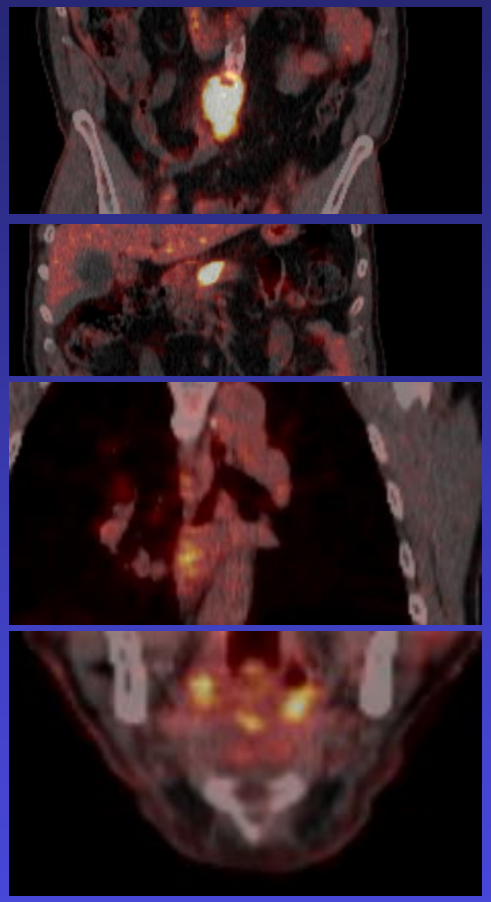

iRPF | iRPF or IgG4-RD?

- Often longitudinal development of multifocal disease
- Role of measuring sIgG4 level unclear
- Low threshold for PET in case of raised sIgG4?

iRPF | Treatment strategy

- Diagnosis based on **TYPICAL** clinical and radiological picture
- **NO** signs of (prior) malignancy

TREATMENT
►If required, (emergency) urine drainage
►Initiate medical Rx

STRICT FOLLOW-UP →
- No response within 6 wk - 4 mo: **reconsider CT-guided biopsy**
  ►Most important diagnostic pitfall malignant lymfoma

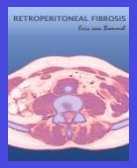

iRPF | Corticosteroids

Reported case series of iRPF patients

- Period 1984-2014, *n* = 44
- **Retrospective, *n* = 41; prospective, *n* = 2; RCT, *n* = 1**
- Overall, 1.273 iRPF patients, 631 of whom (49%) received medical Rx
- Definition of treatment succes in 10 studies only (23%)
- Variable treatment dose/duration

- **<u>Outcome with CSs</u>:**
  - ►Universely good/excellent results with CSs (70-100%)
  - ►Variable relapse rates (0-72%)

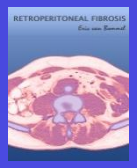

iRPF | Corticosteroids

- Initial high-dose (40-60 mg/day) PDN accepted as the primary treatment
- Probably ≥ 1 year duration

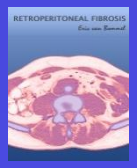

iRPF | CSs plus MMF (Cellcept)

PROSPECTIVE CASE SERIES

- iRPF cases, excluding patients with aneurysmal dilation, *n* = 31
- Clear definition of treatment success
- Average time on study drugs 23.2 (range 6 – 63) mo

- **Treatment:**
  - ►PDN 40 mg/day
  - ►MMF 1000 mg twice-daily

- **Outcome:**
  - ►89% of patients had ≥ 25% volume reduction on CT
  - ►30/32 ureters free of obstruction after 513 days of treatment
  - ►Recurrences 2/28 patients (7%)

Scheel PJ *et al.* **Ann Intern 2011;154:31-36** / Scheel *et al*. **Med Trans Am Clin Clim Ass 2012;123:283-290**.

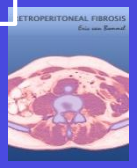

iRPF | Tamoxifen alternative therapy?

Annals of Internal Medicine | ARTICLE

Brief Communication: Tamoxifen Therapy for Nonmalignant Retroperitoneal Fibrosis

2006
N = 19

Eric F.H. van Bommel, MD, PhD; Tadek R. Hendriksz, MD; Antonius W.L.C. Huiskes, MD; and Antoine G.M. Zeegers, MD

Background: Anecdotal case reports suggest tamoxifen as a possible treatment for retroperitoneal fibrosis, but a systematic assessment of its effect is not available.

Objective: To describe the course and outcomes of patients with nonmalignant retroperitoneal fibrosis treated with tamoxifen.

Design: Prospective, consecutive series.

Setting: Single tertiary care referral center.

Patients: 19 patients with nonmalignant retroperitoneal fibrosis treated with tamoxifen from April 1998 through April 2005.

Intervention: Tamoxifen, 20 mg orally twice daily.

Measurements: Clinical improvement, laboratory variables, and follow-up computed tomography (CT) and gallium scan findings.

Results: Fifteen patients reported substantial resolution of symptoms after a median treatment duration of 2.5 weeks. Erythrocyte sedimentation rate and C-reactive protein also improved. Gallium scanning at follow-up showed incomplete disappearance of pathologic gallium-67 activity. Repeated CT scanning showed slow but steady mass regression in 14 of 15 clinical responders. Five patients failed treatment, including 1 patient who improved clinically. Disease recurred in 1 patient who responded to reintroduction of tamoxifen. One patient developed reversible hepatitis.

Limitations: This small observational study did not have a control group.

Conclusion: Tamoxifen may be a viable therapeutic option in the treatment of retroperitoneal fibrosis.

Ann Intern Med. 2006;144:101-106. www.annals.org
For author affiliations, see end of text.

Van Bommel *et al*. Tamoxifen therapy for non-malignant retroperitoneal fibrosis. **Ann Intern med 2006;144:101-106.**

Van Bommel et al. Long-term safety and efficacy of a tamoxifen-based treatment strategy for idiopathic retroperitoneal fibrosis. **Eur J Intern Med. 2013; 24:444-450.**

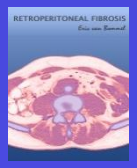

iRPF | Tamoxifen alternative therapy?

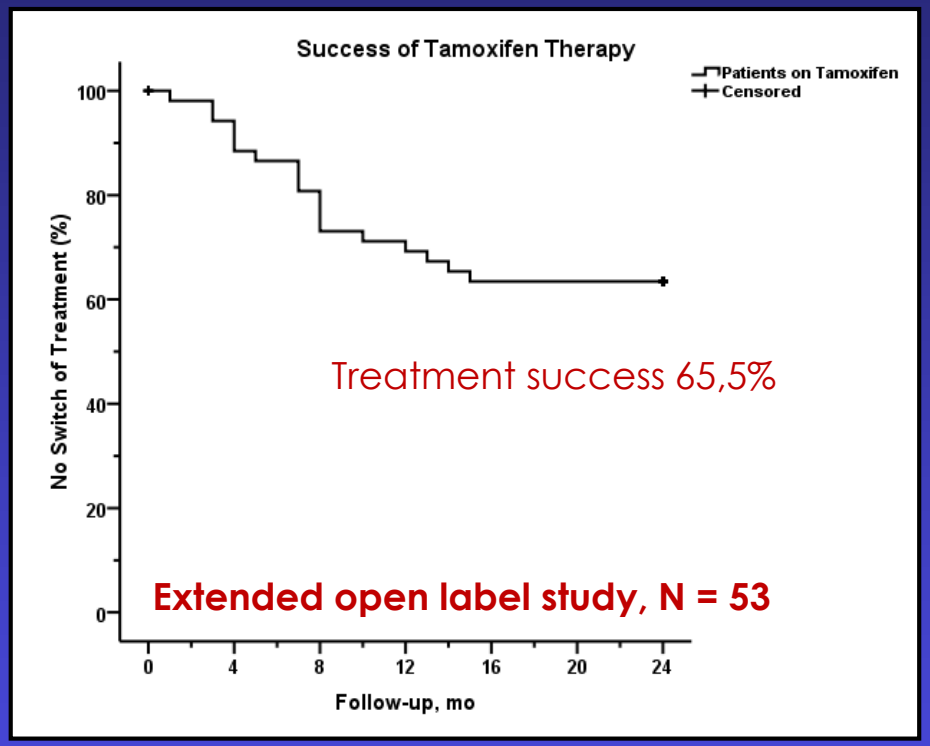

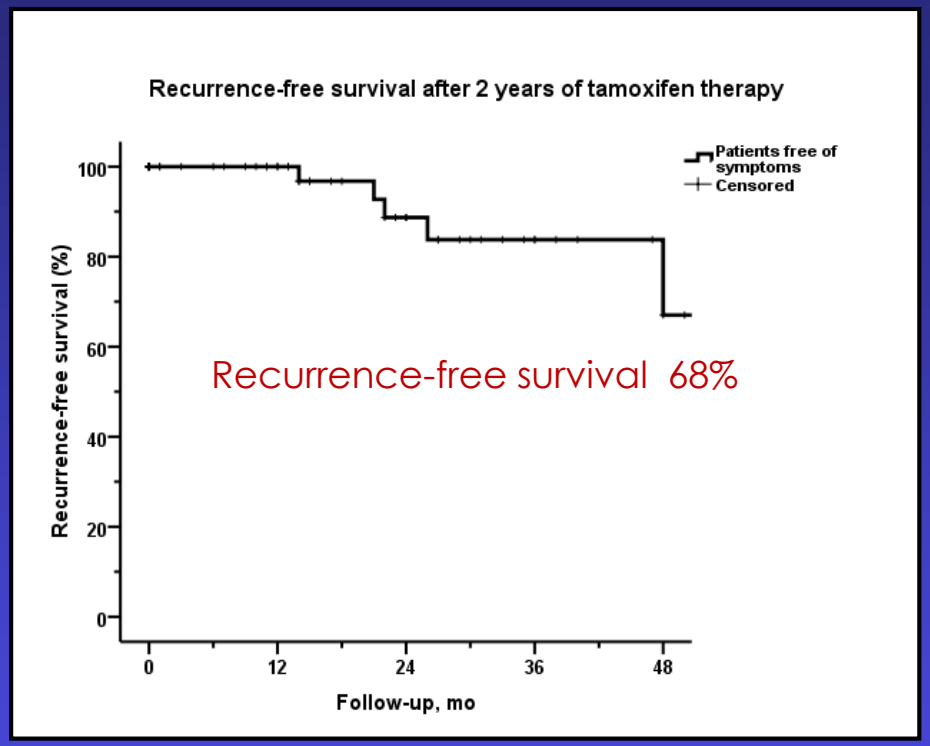

Van Bommel *et al*. Tamoxifen therapy for non-malignant retroperitoneal fibrosis. **Ann Intern med 2006;144:101-106.**

Van Bommel et al. Long-term safety and efficacy of a tamoxifen-based treatment strategy for idiopathic retroperitoneal fibrosis. **Eur J Intern Med. 2013; 24:444-450.**

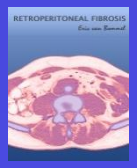

iRPF | Randomized controlled trial

- Induction Rx prednisone 1 mg/kg/day for 4 wks
- Randomized to further 8 months:
  - ▶Tapering dose of prednisone
  - ▶Tamoxifen
- **Primary endpoint**: relapse rate at 8 months

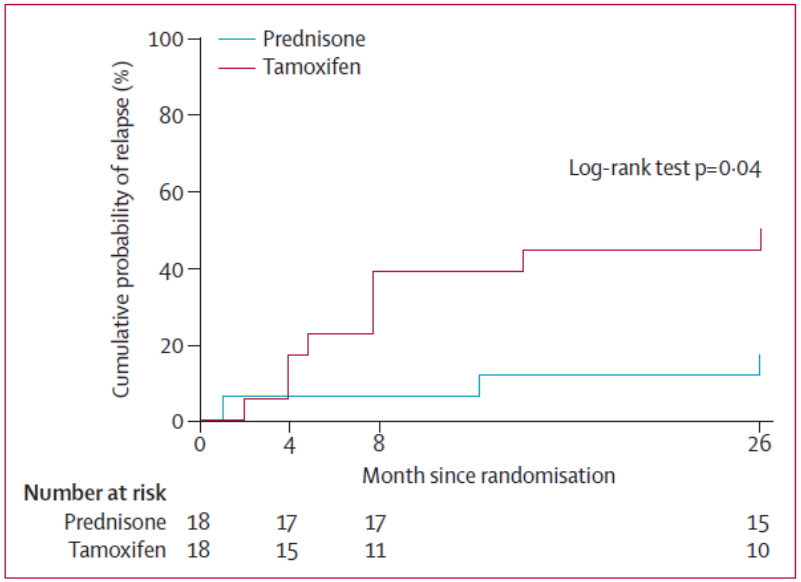

Figure 3: Kaplan-Meier estimate of the time from randomisation to the first relapse in the two treatment groups

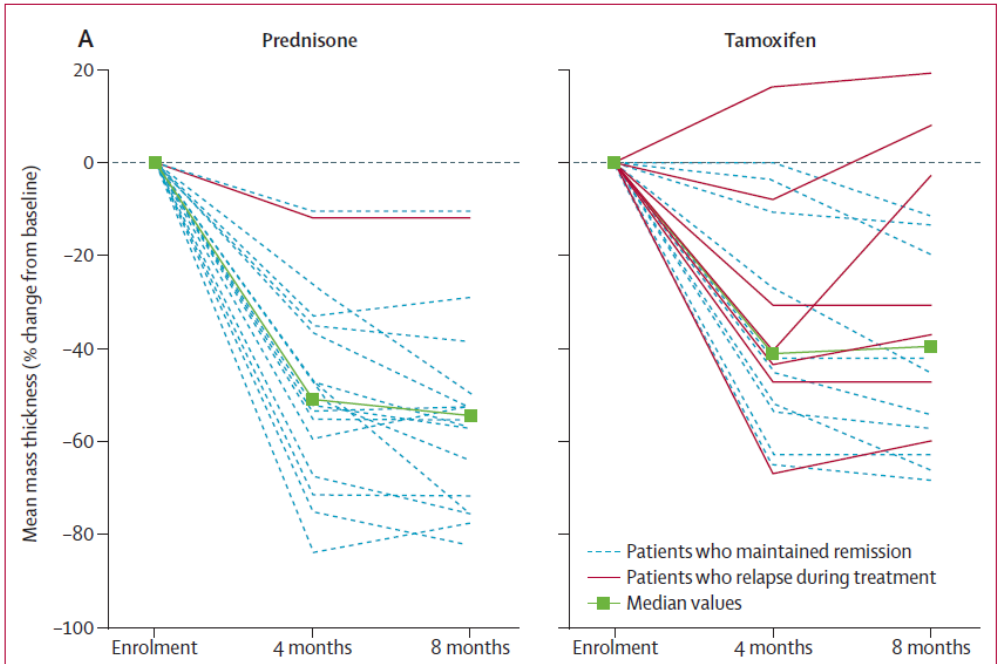

Probability of relapse

Mass regression during FU

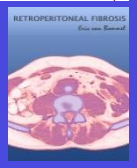

Vaglio A *et al.* **Lancet 2011;378:338-346.**

iRPF | Randomized controlled trial

- PDN more efficious then TMX in preventing relapse

►How to identify TMX responders?

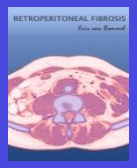

Vaglio A *et al.* **Lancet 2011;378:338-346.**

iRPF | PDN vs. TMX monotherapy

	PDN	TMX	*P*-value
Number, *n*	50	68	
Amelioration of symptoms, *wk*	2.0 (0.8-3.8)	4.0 (2.0-6.0)	< 0.01
Mass regression 1st FU CT scan*, *n* (%)	42 (84)	43 (68.3)	0.05
Duration of stenting, *mo*	7 (4-15)	8.5 (5.5-12.5)	0.95
Treatment success, *n*/total *n* (%)	31/44 (70.5)	28/48 (58.3)	0.23

	PDN	TMX	*P*-value
Duration of treatment, *mo*	14 (8-18)	24 (24-24)	
Recurrence, *n*/total *n* (%)	21/31 (67.7)	6/28 (21.4)	< 0.01
Post-treatment FU, *mo*	55 (23-122)	39 (19-50)	0.07

FE van der Bilt, TR Hendriksz, WAG van der Meijden, LG Brilman, EFH van Bommel. Outcome in patients with idiopathic retroperitoneal fibrosis treated with corticosteroid or tamoxifen Monotherapy.
Clinical Kidney Journal 2016;9(2):184–191

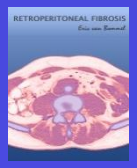

iRPF | PDN vs. TMX monotherapy

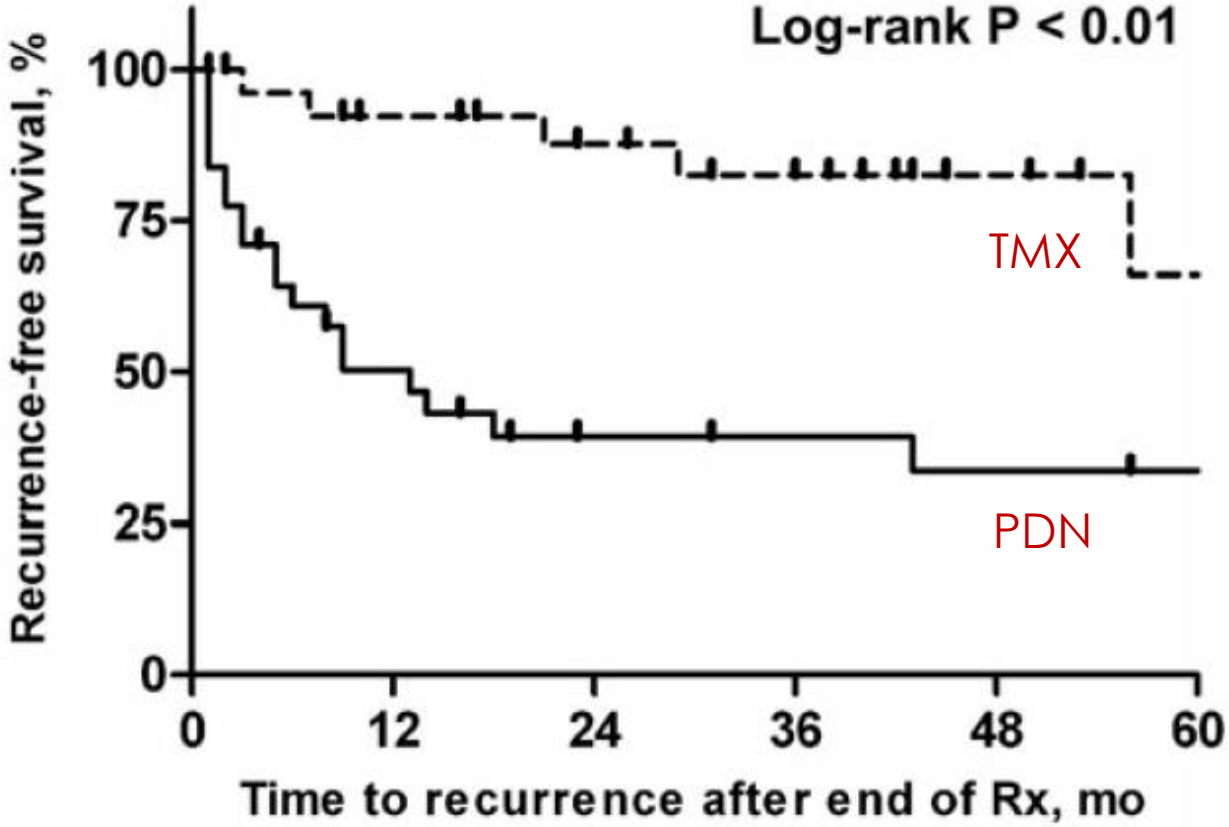

Patients at risk						
Prednison	31	17	10	8	7	7
Tamoxifen	28	23	19	15	10	5

FE van der Bilt, TR Hendriksz, WAG van der Meijden, LG Brilman, EFH van Bommel. Outcome in patients with idiopathic retroperitoneal fibrosis treated with corticosteroid or tamoxifen Monotherapy.
Clinical Kidney Journal 2016;9(2):184–191

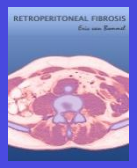

iRPF | PDN vs. TMX monotherapy

Should these patients be treated longer?

FE van der Bilt, TR Hendriksz, WAG van der Meijden, LG Brilman, EFH van Bommel. Outcome in patients with idiopathic retroperitoneal fibrosis treated with corticosteroid or tamoxifen Monotherapy.
Clinical Kidney Journal 2016;9(2):184–191

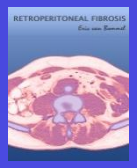

iRPF | Relapsing/refractory cases

IMMUNOSUPPRESSANTS

- Methotrexate
  - Specific study in relapsing disease (*n*=16)[1]
- (Mycophenolate mofetil)
  n = 31 patients
- (Cyclophosphamide)
  n = 26/ *n* = 35 patients

BIOLOGICALS

- Rituximab (anti-CD20)[2]
- Infliximab (anti-TNF)
- Tocilizumab (anti-IL6)

} Only anecdotal CRs

[1]Alberici F et al. Methotrexate plus prednisone in patients with relapsing idiopathic retroperitoneal fibrosis. **Ann Rheum Dis. 2013 Sep 1;72(9):1584-6.**

[2]Wallwork R et al. Rituximab for idiopathic and IgG4-related retroperitoneal fibrosis. **Medicine (Baltimore). 2018 Oct;97(42):e12631.**

iRPF | Relapsing/refractory cases

Table 3

Treatment response.

RTX +/- CS, IgG4-related RPF, n=19/iRPF, n=7

Clinical and radiologic response	
Symptomatic response (n=19)	19 (100%)
Radiographic response* (n=25)	22 (88%)†
Stable (if no reduction in size, n=3)	3 (100%)
Mean change in size in 2 dimensions among those with available images (n=18, SD)	23% (21)
Reduction of ≥ 25% among those with available images (n=18)	5 (28%)
Stent or PCN removed (n=10)	4 (40%)

iRPF | Relapse rate

Raffiotta *et al*, AJKD 2019

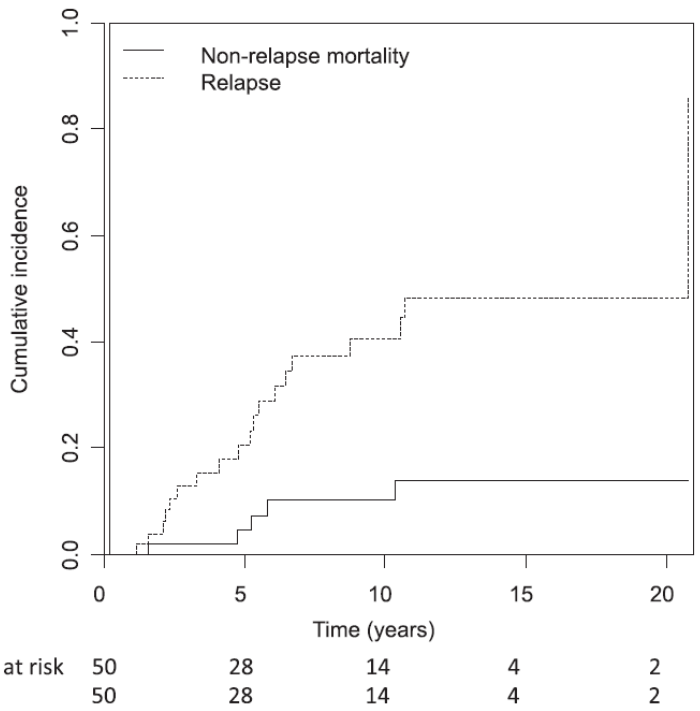

Figure 2. Cumulative incidences of relapse and nonrelapse mortality of patients with idiopathic retroperitoneal fibrosis. Nonrelapse mortality was defined as the probability of dying without previous occurrence of relapse.

- ▶Median FU 8.9 yrs
- ▶Relapse in 19/50 pts (38%)

1st relapse:
median 5.19 yrs after start Rx

Relapse cumulative incidence:
5 jrs 21% / 10 yrs 41% / 15 yrs 48%

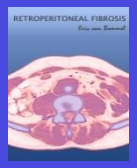

iRPF | Relapse rate

Raffiotta *et al*, AJKD 2019

Some questions/concerns

- Both responsive and nonresponsive pts at 1yr Rx were evaluated for evaluation of relapse rate
- Unclear when/why pts received additional IS agent
- Duration of Rx unknown

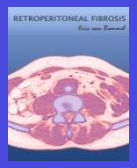

iRPF | Conclusions (1)

- iRPF multifactorial/multifaceted disease
- Chronic periaortitis may be the preferred term in cases associated with severe atherosclerosis
- Routine biopsy not required
- Role of IgG4 in iRPF as yet unclear

iRPF | Conclusions (2)

- Initial high-dose PDN primary treatment, duration ≥ 1 yr
- Tamoxifen valuable alternative for long-term CSs (2x20 mg/2 yr)
- Relapses are frequent!
- In difficult-to-treat cases, combined Rx (PDN+MMF, MTX and/or TMX) may be usefull
- RTX may be used for refractory cases; role of other biologicals in relapsing disease unclear